


THE NEW YORK EYE



190 YEARS OF CARING

TRADITION OF EXCELLENCE

AND EAR INFIRMARY

DEPARTMENT OF OPHTHALMOLOGY

PRESENTS

**16TH ANNUAL
RESIDENT AND FELLOW
RESEARCH DAY**

FRIDAY, MAY 18, 2012 8:00AM - 1:00PM

16th Annual Resident and Fellows Research Day

May 18, 2012

Lauren Schneider, MD	Oxygen Saturation within Retinal Vessels Pre- and Post-Intravitreal Injection with Bevacizumab using the Oxymap Retinal Oximeter	1
Faye Knoll, MD	Early Transitioning to Deep Anterior Lamellar Keratoplasty (DALK)	2
Chirag R. Patel, MD	Long-Term Graft Survival Rates in Descemet's Stripping Endothelial Keratoplasty	3
Amar Patel, MD	A Retrospective Study of Idiopathic Intracranial Hypertension and Metabolic Syndrome: Do They Co-Exist?	4
Ben Bert, MD	Weather and its Effect on Patient Attendance to a Walk-In Ophthalmology Clinic	5
Gennady Landa, MD	Microglia in Retina – Can we see them in vivo?	6
Christopher Seebruck, MD	Non-Uveitis Specialists Survey on the Knowledge of Immunosuppressive Agents for Uveitis	7
Ronald Tongbai, MD	Transcriptional Regulatory Network Analysis of Uveal Melanoma	8
Kevin Rosenberg, MD	Dimensions of the Neural Canal at the Optic Nerve Head in Non-arteritic Ischemic Optic Neuropathy Compared to Normal Subjects	9
Kasra Eliasieh, MD	Safety and Efficacy of Fine Needle Aspiration Biopsy in the Diagnosis of Infiltrative and Inflammatory Processes Involving the Lacrimal Gland	10
Robert Lowe, MD	Optical Coherence Tomography and Macular Holes	11
Gintien Huang, MD	IOP response of Nd-YAG Laser to Prophylactic Treatment of Iopidine 1%	12
Peter Chang, MD	Intravenous Immunoglobulin (IVIg) in the Treatment of Refractory Ocular Catricialpemphigoid (OCP)	13
Travis Jenkins, MD	Retained Nuclear Fragments in the Anterior Vitreous after Routine Phacoemulsification	14
Alice Hong, MD	Risk Factors for Intra-operative Complications in Resident Performed Phacoemulsification Cataract Surgery at the New York Eye and Ear Infirmary	15

Anu Patel, MD	Retinal Oximetry in Diabetic Retinopathy	16
Dan Yin, MD	Detection of Herpes Simplex Virus-1 (HSV-1) in failed Descemet's Stripping Automated Endothelial Keratoplasty (DSAEK) Grafts by real-time Polymerase Chain Reaction (PCR)	17
Omar Ozgur, MD	Geo-mapping Direct Animal and Insect Attacks Affecting the Eye using Google Earth, a Feasibility Study looking at Geographic Information Systems in Ophthalmology	18
Apurva Patel, MD	Risk Factors for Retinal Neovascularization in Patients with Uveitis	23
Ambika Hoguet, MD	Endocrine Mucin-Producing Sweat Gland Carcinoma of the Eyelid: Diagnostic and Prognostic Considerations	24
Joseph Tseng, MD	Acetazolamide for the Management of Uveitic Macular Edema	25
Yogita Kashyap, MD	Adult Tearing Patients Managed Successfully With Primary Monocanalicular Intubation: Follow-up Study	26
Kateki Vinod, MD	Pars Plana Baerveldt Implantation for Refractory Childhood Glaucomas: A Follow-up Study	27
Timothy Sullivan, MD	Enhanced Depth Imaging Optical Coherence Tomography of Central Optic Disc Pits	28
Ella Leung, MD	Macular Leakage and Peripheral Vascular Leakage on Ultra-Wide Field Fluorescein Angiography	29
Wendy Huang, MD	Analysis of Refractive Outcomes of Secondary Intraocular Lens Placement in a Tertiary Referral Center	30
Omar Faridi, MD	Focal Lamina Cribrosa Defects and Glaucomatous Visual Field Progression	31
Anthony Hsu, MD	Risk Factors for Focal Lamina Cribrosa Defects in Glaucoma	33
Andrew Greenberg, MD	Efficacy Of The Amsler Grid Test In Evaluating Glaucomatous Central Visual Field Defects	35
Cinthi Pillai, MD	Genetic Screening of LOXL1 Polymorphisms in Exfoliation Syndrome (XFS) Suspects (XFSS)	38
Reshma A. Mehendale, MD	Variability and Relationships of Lamina Cribrosa Size, Position and Depth in Normal Subjects	40
David Warrow, MD	Treatment of Acute Subretinal Hemorrhage with Subretinal Tissue Plasminogen Activator Administered via Pars Plana Vitrectomy and Gas Fluid Exchange	41

Oxygen Saturation within Retinal Vessels Pre- and Post-Intravitreal Injection with Bevacizumab using the Oxymap Retinal Oximeter

Author: Schneider L, MD, Sripsema N, Bhoomibunchoo C, MD, Rosen R., MD

PURPOSE: The purpose of this study is to determine the effect of intravitreal bevacizumab on oxygen saturation within primary and secondary retinal vessels.

METHODS: This study is a retrospective review. The Oxymap T1 was used to quantitatively measure oxygenation in retinal vessels pre-injection and one to two weeks post-injection of intravitreal bevacizumab. Oxymap is an investigational device. Blood changes its color and optical density due to its level of oxygenated hemoglobin. The Oxymap Analyzer captures two simultaneous images at 570nm (oxygen insensitive) and 600nm (oxygen sensitive). The ratio of these two optical densities at points along a vessel is linearly related to its oxygen saturation.¹ The software superimposes a colored oxygenation map on all 50° images. Vessel segments can be selected for detailed numerical analyses. All primary and secondary vessels were selected to generate the mean arterial and venous oxygen saturation, respectively.

RESULTS: This study included 13 eyes of 13 patients receiving intravitreal bevacizumab for macular edema. Pre-injection vessel oxygenation was compared directly to post-injection oxygenation. The mean age was 59.92 ± 12.41 years, 61.5 % were male, 53.8% were diabetic, 76.9% were hypertensive, and 7.7% had glaucoma. Mean pre-injection arterial and venous blood oxygenation in primary and secondary vessels was $102.19\% \pm 4.84\%$ and $65.56\% \pm 7.22\%$, respectively, and mean post-injection arterial and venous blood oxygenation was $100.99\% \pm 4.84\%$ and $64.78\% \pm 10.47\%$, respectively. Paired t-tests did not reveal a statistically significant difference between pre- and post-injection oxygenation ($p = 0.697$ for arterial oxygenation; $p = 0.307$ for venous oxygenation).

CONCLUSION: Based on the Oxymap data, intravitreal bevacizumab does not appear to adversely affect retinal arterial or venous oxygenation in primary and secondary vessels in patients receiving this treatment for macular edema.

1. Beach JM, Schwenzer K, Srinivas S, Kim D, Tiedeman JS. Oximetry of retinal vessels by dual-wavelength fundus imaging: calibration and influence of pigmentation. *J Appl Physiol.* 1999 Feb;86(2):748-58.

Early Transitioning to Deep Anterior Lamellar Keratoplasty (DALK)

Authors: Faye Knoll, MD, Chirag Patel, MD, Elaine Wu, MD, David C. Ritterband, MD, Richard S. Koplun, MD, John A. Seedor, MD

Purpose: To gain a better understanding of an experienced corneal surgeon's learning curve when transitioning from penetrating keratoplasty (PK) to deep anterior lamellar keratoplasty (DALK) and compare the clinical success to the literature.

Method: A retrospective chart review of all eyes undergoing DALK by one surgeon was reviewed. The clinical and anatomic success was documented and compared to the literature with more experienced surgeons in the DALK technique.

Results: Twenty-one eyes were reviewed. Thirteen of the 21 patients were male and 8/21 were female. The average age was 36. The indication for surgery in 19/21 eyes was keratoconus. One patient had lattice dystrophy and 1 patient had an HSV scar. The overall conversion rate to PK at the time of surgery was 43% (9/21). This is in comparison to a conversion rate of approximately 15% in the literature. After the first 6 cases were completed, our conversion rate decreased to 20%. After the first 8 cases were completed, our conversion rate dropped to 15%. Average best corrected visual acuity at the end of follow up was ~ 20/50 as compared to about 20/40 or better reported in the literature.

Conclusion: DALK is a safe alternative to PK. While there is a learning curve during the transition period from PK to DALK, in our series it nears the published average in the literature after 8 cases.

Long-Term Graft Survival Rates in Descemet's Stripping Endothelial Keratoplasty

Chirag R. Patel, MD, David C. Ritterband, MD, Faye Knoll, MD, Elaine Wu, MD, John A. Seedor, MD, Richard S. Koplun, MD. The New York Eye and Ear Infirmary, New York, NY.

Purpose: To determine the long-term survival rates of corneal grafts after Descemet stripping automated endothelial keratoplasty (DSAEK).

Methods: A retrospective chart review of all patients that underwent DSAEK by two experienced corneal surgeons at the New York Eye and Ear Infirmary over a 2.5-year period from July 1, 2006 through December 31, 2008. Only patients with a minimum of 36 months of follow-up were included in the study. Patients that developed primary graft failure following surgery, defined as failure of the graft to clear at any point post-operatively, were excluded.

Results: 67 eyes of 65 patients were found to meet the inclusion criteria. 56.9% of the patients were female and mean age at time of procedure was 69.4 years (range 33-89 years). Indications for DSAEK included: Fuch's dystrophy (40.3%), pseudophakic bullous keratopathy (26.9%), previously failed DSAEK (14.9%), corneal endothelial failure from other causes (11.9%), previous failed penetrating keratoplasty (3.0%), aphakic bullous keratopathy (1.5%), and trauma (1.5%). The overall 3-year graft survival rate was 80.6% (n=54). The survival rate was highest in Fuch's dystrophy (96.3%), decreasing to 77.8% in pseudophakic bullous keratopathy, and down to a low of 37.5% in those with endothelial failure from anterior chamber hardware (glaucoma drainage devices) or disorganized anterior segments (PAS, abnormal pupils). Eyes with pre-existing glaucoma had a significantly higher risk of failure with a survival rate of 61.9% compared to 91.1% in eyes without glaucoma ($p < 0.05$).

Conclusions: Greater than three-year survival rates of DSAEK grafts are similar in this series to previously published results with lower rates of failure in eyes with Fuch's dystrophy compared to those with other causes of endothelial dysfunction. Eyes with glaucoma were at significantly higher risk for graft failure following DSAEK.

A Retrospective Study Of Idiopathic Intracranial Hypertension and Metabolic Syndrome: Do They Co-Exist?

Author Block: Amar P Patel, MD¹, Nona Ionita, MD², Rudrani Banik, MD¹, ¹Department of Ophthalmology, New York Eye and Ear Infirmary, New York, NY ²Department of Ophthalmology, Bronx-Lebanon Hospital Center, New York, NY

Purpose: To determine whether there is an association between Idiopathic Intracranial Hypertension (IIH) and Metabolic Syndrome (MS).

Methods: A retrospective review was performed of all patients with a diagnosis of IIH seen between July 2010 and October 2011. The primary outcome measure was presence or absence of MS as defined by the American Heart Association and the National Heart, Lung and Blood Institute.

Results: 51 female patients were included, 31 (71%) of which met the criteria for MS. Mean age at diagnosis of the MS group was 35.3 years versus 29.5 years in the non MS group ($p=.060$). A significant difference was found between triglyceride level, fasting blood glucose, hemoglobin A1c, and systolic blood pressure ($p= 0.0020, 0.0014, 0.0059, 0.000045, 0.014$, respectively) of the MS and non MS patients. Body mass index, waist circumference, opening pressure, high density lipoprotein level, and diastolic blood pressure were not significantly different between the two groups.

Conclusions: A high percentage of patients with IIH also have MS, suggesting an association. Patients with IIH and MS had higher triglyceride levels, fasting blood glucose, hemoglobin A1c, and systolic blood pressure compared to patients without MS. Whether MS is a co-morbidity of IIH or plays a role in the pathogenesis of IIH remains to be investigated

Weather and its Effect on Patient Attendance to a Walk-In Ophthalmology Clinic

B. Bert, MD

Department of Ophthalmology, The New York Eye and Ear Infirmary

Purpose: To evaluate how weather affects patient attendance of the walk-in general clinic and urgent care at the New York Eye and Ear Infirmary.

Methods: Retrospective review of clinic attendance and National Climatic Data Center (NCDC) data for the calendar year 2009. We excluded weekend days and holidays, with all other weekdays included.

Results: 253 non-holiday weekdays were included equaling 31,425 patient visits; an average of 124.2 patients per day. During all of 2009 the average temperature in New York City, NY was 53.68 degrees. When evaluating for comfortable days (average temperature equal to 55 degrees Fahrenheit or above) versus cold days (average temperature less than 55 degrees Fahrenheit) we found that there were fewer patients on colder days 119 ± 21.05 versus 130 ± 22.98 on warmer days with a $P < 0.0001$. However, on rainy days patient attendance was 125 ± 23.4 on dry days versus 123 ± 21.5 on rainy days with a $P = 0.61$.

Conclusion: A colder outside temperature will decrease patient attendance to a walk-in ophthalmology clinic, while precipitation has no affect.

Microglia in retina – can we see them in vivo?

Gennady Landa,^{1,2} Jonathan Barnett,¹ Patricia MT Garcia,^{1,2} Richard B. Rosen,^{1,2}

¹Retina Center, Department of Ophthalmology, New York Eye & Ear Infirmary, New York, NY, USA, ²Department of Ophthalmology, New York Medical College, Valhalla, NY, USA

Purpose: Histological studies have suggested that only microglial cells have their cell bodies located in the inner plexiform layer (IPL), which functional significance is not well understood. We propose that IPL reflectivity may be related with the status of microglial population. Our purpose was to evaluate IPL reflectivity variations among patients with different outer retinal diseases in vivo.

Methods: Using High Resolution Spectral Domain OCT (SD-OCT) imaging, the inner plexiform layer appears highly reflective and can be identified between the ganglion cell layer and inner nuclear layer. Normal subjects, patients with dry AMD, geographic atrophy, wet AMD and patients with retinitis pigmentosa were imaged using high resolution SD OCT and IPL reflectivity was retrospectively analyzed using Photoshop software. Mean luminosity, which is the brightness of the IPL reflectivity, was the primary outcome measurement.

Results: Sixty-nine eyes of 62 patients composed study population. In comparison to normal subjects (91.7 ± 10.4), the mean luminosity of the IPL was significantly lower in patients with geographic atrophy (74.0 ± 15.8 ; $p=0.018$) and retinitis pigmentosa (71.8 ± 19.1 ; $p=0.0003$).

Conclusions: Evaluation of the IPL reflectivity may be important in ocular diseases with primary involvement of outer retina, such as AMD and RP. The microglial status in vivo can be indirectly evaluated based on alteration in reflectivity of the IPL layer on SD-OCT. Further studies are warranted to further investigate a role of microglia in patients with various ocular diseases.

CME question:

Which retinal layer can be used for indirect evaluation of microglial status on SD-OCT?

1. Ganglion cell layer
2. **Inner plexiform layer**
3. Outer plexiform layer
4. Inner nuclear layer

Non-Uveitis Specialists Survey on the Knowledge of Immunosuppressive Agents for Uveitis

Author Block *Christopher J. Seebruck*¹, *Sanjay Kedhar*^{1,2}, *Paul Latkany*¹, *Vicente A. Diaz*^{1,3}, *John Mauro*¹, *C. M. Samson*^{1,2}. ¹Ophthalmology, New York Eye & Ear Infirmary, New York, NY; ²Ophthalmology, New York Medical College, Valhalla, NY; ³Ophthalmology, Yale, Hew Haven, CT.

Purpose: Uveitis is an inflammatory disorder of the iris, ciliary body and choroid that can cause significant visual disability and require aggressive immunomodulatory therapy. Insufficient knowledge among physicians and an underestimation of the burden and consequences of uveitis remain a potential barrier to progress in preventing blindness due to uveitis. Thus, we carried out this survey to analyze the knowledge of non-uveitis specialist ophthalmologists, regarding their knowledge on the indications, safety and role of IMT in uveitis.

Methods: Forty-one ophthalmologists practicing in New York were presented with a 13-question re-survey. Survey questions were aimed at discerning the perceptions and knowledge regarding immunosuppressive therapy as an example of current standard of care. Participation in the survey was voluntary and the identity of the participants was kept anonymous.

Results: Forty-one practicing ophthalmologists re-surveyed from greater New York saw on average 14.7 uveitis patients over a 3-month period and referred 17.1 uveitis patients to a specialist per year. Steroid unresponsiveness was quoted as the main indication for immunosuppressive therapy (68.3%). About 12% were not sure of the indications and the average level of confidence regarding the indication of these agents was 2.8 out of 5. Myelosuppression (22.4%) and immunosuppression (26.9%) were the most common concern for toxicity and side effects of immunomodulatory therapy with an average level of confidence of 2.1 out of 5.

Conclusions: There still exist some ophthalmologists in the community, despite clinical trials, evidence in literature, and world expert opinions, that are not aware that IMT therapy constitutes standard of care in cases of severe uveitis unresponsive or intolerable to steroids.

Author Disclosure Information: Christopher J. Seebruck, None; Sanjay Kedhar, None; Paul Latkany, None; Vicente A. Diaz, None; John Mauro, None; C. M. Samson, Abbot Laboratories (C), Adesso Biosciences (C), CLS Pharmaceuticals (C), Eyegate Pharmaceuticals (C), Lux Biosciences (C), Novartis (C), PCAsso (C)

Transcriptional Regulatory Network Analysis of Uveal Melanoma

Ron Tongbai, MD and Jennifer Vargas

Purpose: Uveal melanoma is the most common form of intraocular melanoma in adults and metastasis to the liver and lungs is associated with a worse prognosis. A study by Onken et al utilized microarrays to characterize the gene expression profiles of tumors which metastasized and compared them with the gene expression profiles of tumors which did not metastasize. The study identified specific genetic signatures which discriminated between tumors that do and do not metastasize. The study provides an important insight into the molecular pathways and biological processes that govern the establishment and growth of these metastases.

Methods: Promoter region sequences from a 600 bp region (-500 bp upstream to +100 bp downstream) were obtained for each gene in each of the gene lists using the ProSpector free web-based promoter annotation tool (4). The promoter regions of each of the gene signatures were analyzed for matches to approximately 300 position weight matrices (TFBS) using the MatInspector module of the GEMS LaunchER 4.1 (Genomatix, Munich, Germany).

Results: A regulatory profile was generated based on the methods described above. Each of the gene lists were analyzed to generate p-values representing the degree of statistical enrichment for each of the approximately 300 TFBS in the promoter regions of these genes as described in the methods.

Conclusions: These results provide an important insight into the cell biology that governs the regulatory networks involved in uveal melanoma. Transcription factors implicated in the cell biology of uveal melanoma include AP2, ATF, and MapK/ERK.

Dimensions of the Neural Canal at the Optic Nerve Head in Non-arteritic Ischemic Optic Neuropathy Compared to Normal Subjects

Kevin Rosenberg, MD, Sung Chul Park, MD, Daniel Su, MD, Rudrani Banik, MD, Jeffrey Liebmann, MD, Robert Ritch, MD

Purpose: To compare neural canal dimensions at the optic nerve head between patients with non-arteritic anterior ischemic optic neuropathy (NAION) and normal subjects using enhanced depth imaging optical coherence tomography (EDI OCT).

Methods: Complete ophthalmologic examinations were performed including horizontal and vertical serial EDI OCT of the optic nerve head for the eye with NAION and for one randomly selected eye of healthy subjects. Neural canal dimensions, including Horizontal and vertical diameters of the optic disc, Bruch's membrane opening (BMO), lamina cribrosa, and narrowest neural canal opening (NCO), were measured from EDI OCT cross-sectional images and compared between the eyes with NAION and healthy eyes.

Main Outcome Measures:Results: Sixteen eyes from 16 patients with NAION (10 women; mean age, 61 ± 13 yr) and 43 eyes from 43 normal subjects (21 women; mean age, 44 ± 15 yr) were included. In the NAION group, corrected visual acuity ranged from counting fingers at 6 inches to 20/20, and 24-2 visual field mean deviation of 13 eyes was -16.3 ± 11.1 dB (three eyes had Goldmannperimetry because of poor vision). All neural canal dimension measurements (horizontal and vertical diameters of the optic disc, BMO, lamina cribrosa and narrowest NCO) showed excellent measurement reproducibility (intraclass correlation coefficient: 0.921-0.972). Mean horizontal and vertical diameters of the optic disc, BMO, and narrowest NCO were smaller in NAION patients compared to those in normal subjects, but their differences did not reach statistical significance, both before and after controlling for age and gender (all $P>0.1$). Mean horizontal and vertical diameters of the lamina cribrosa were significantly smaller in the NAION group compared to those in the normal group, both before and after controlling for age and gender (all $P<0.001$).

Conclusions: Crowding of the neural canal at the lamina cribrosa level may be a risk factor for NAION and play a role in its pathophysiology.

Safety and efficacy of fine needle aspiration biopsy in the diagnosis of infiltrative and inflammatory processes involving the lacrimal gland

Authors: Kasra Eliasieh, MD, Meredith Allen, MD, Robert Della Rocca, MD, Tatyana Milman, MD, Codrin Iacob, MD, Flora Levin, MD, David Della Rocca, MD

Purpose: To determine whether fine needle aspiration biopsy of infiltrative and inflammatory processes involving the lacrimal gland is as diagnostically efficacious as open biopsy. The secondary objective is to examine the safety profile of this procedure.

Methods: Fine needle aspiration was performed on 10 patients who were diagnosed with lacrimal gland enlargement requiring open biopsy. The procedures were performed in an operating room under general anesthesia. Using sterile technique, a 25 gauge needle on a syringe was passed transcutaneously into the lacrimal gland. The needle was twisted and withdrawn, and no more than one or two passes were made. Next, an anterior orbitotomy was performed, exposing the lacrimal gland. A 25 gauge needle was then passed directly into the lacrimal gland for another sample. Then a sample of lacrimal gland tissue was excised. Both transcutaneous and direct fine needle aspiration biopsies (FNAB), and the direct open biopsy specimens were studied and diagnosed by a pathologist at the New York Eye and Ear Infirmary.

Results: The patients ranged in age from 21 years to 66 years, and there were 5 women and 5 men. Results from the standard open biopsies showed 8 cases consistent with idiopathic orbital inflammation (IOI), 1 case of B-cell lymphoma, and 1 case of sarcoidosis. None of the transcutaneous or direct FNAB specimens yielded enough tissue to make any diagnoses. There were no surgical complications in any of the cases.

Conclusions: In our experience, neither transcutaneous nor direct FNAB provided enough tissue to lead to a diagnosis in cases of lacrimal gland enlargement. Although FNAB has been shown to be diagnostically effective in other tissues, we believe there are several reasons why it was not effective in our series. Firstly, a lack of experience with FNAB of the lacrimal gland may have resulted in poor yield. Also, the needle was passed only once or twice while taking the sample. This may have been insufficient to acquire enough tissue. And finally, 80% of our cases were confirmed as IOI, which can cause extensive scarring of the lacrimal gland, making it difficult to diagnose with FNAB. Our study did show that FNAB is a safe procedure for the lacrimal gland as there were no surgical complications. Further studies should be pursued to determine whether it can be beneficial in diagnosing lacrimal gland enlargement.

Optical Coherence Tomography and Macular Holes

Robert Lowe, M.D., Ronald Gentile, M.D.

Introduction: Optical coherence tomography (OCT) has revolutionized how we diagnose and classify macular holes. A book chapter was written to describe the use of OCT as an adjunctive aid in understanding macular hole development, repair, and visual outcome.

Methods: Literature review

Results: The introduction of OCT has allowed high resolution imaging of macular holes, enabling further understanding of the relationship between the vitreous and retina during the formation of a macular hole. Anterior –posterior contraction of the cortical vitreous from the fovea in time-lapsed OCT morphing videos may be the initiating event in idiopathic macular hole formation. Progression and enlargement of the macular hole may occur as a result of hydration of the inner retina with the formation of cystic edema at the edges of the macular hole. Stage 1A macular holes on OCT were found to have a triangular detachment of the foveola that could represent a detachment of the posterior tips of the cone outer segments. The roof or inner layer of the stage 1B macular hole remains intact, and the outer layer develops a break with the retinal pigment epithelial layer becoming devoid of photoreceptors. OCT can be used to show a break in the roof of a stage 2 full-thickness macular hole. Furthermore, OCT can demonstrate full thickness macular holes in stage 3 and 4. The use of OCT in the immediate postoperative period may help limit face down positioning once the macular hole appears closed on OCT. Macular holes may close through the formation of a bridge of neural tissue. In bridge formation, a seal is created and the subretinal and intraretinal fluid is reabsorbed to close the macular hole. In addition, OCT imaging of surgically closed macular holes have been showed to aid in predicting visual outcome. The preservation of the external limiting membrane (ELM) layer and photoreceptor inner and outer segment (IS/OS) junction seem to predict visual acuity and photoreceptor cell survival. This is believed to be the case since the ELM represents the junction between the Müller cells and photoreceptor cells and the IS/OS junction represents the integrity of photoreceptor alignment.

Conclusions: OCT has greatly aided in the diagnosis and classification of macular holes. More recently with higher resolution OCT, mechanism of macular hole formation and closure in addition to a better understanding of postoperative visual prognosis have been described.

IOP response of Nd-YAG laser to prophylactic treatment of iopidine 1%

Gintien Huang, MD

Purpose: To evaluate the IOP response with Nd:YAG laser after prophylactic treatment with iopidine.

Methods: We retrospectively reviewed the response of IOP by applanation tonometry before and 1 hour after Nd:YAG laser iridotomy and capsulotomy with pretreatment of iopidine 1%. A total of 80 eyes underwent Nd:YAG laser with 69 eyes undergoing laser iridotomy and 11 eyes undergoing capsulotomy.

Results: A total of 80 eyes underwent Nd:YAG laser. 49 (61.3%) patients had lower post-laser IOP with a mean drop of 3.9 mmHg, 8 (10%) patients had no change, and 23 (28.8%) had higher post-laser IOP with a mean increase of 3.0 mmHg. Of the 80 patients, 69 had anatomically narrow angles or chronic angle closure glaucoma requiring Nd:YAG laser iridotomy. Of that subgroup, 44 (63.8%) patients had lower post-laser IOP with a mean drop of 4.2 mmHg, 7 (10.1%) patients had no change, and 18 (26.1%) had higher post-laser IOP with a mean increase of 3.2 mmHg. 11 patients had Nd:YAG laser capsulotomy. Of that subgroup, 5 (45.5%) patients had lower post laser IOP with a mean drop of 1.4 mmHg, 1 (9.1%) patient had no change, and 5 (45.5%) patients had higher post-laser IOP with a mean increase of 2.2 mmHg.

Conclusion: Nd:YAG laser showed an increase in IOP in only 28.8% of eyes and 26.1% in laser iridotomies, with the highest IOP rise being 8mmHg. A higher percentage with Nd:YAG capsulotomies had an increase of IOP at 45.5% but is limited by the small sample size. This raises the question for the need for prophylactic treatment with iopidine 1% and time spent for both the patient and physician checking a post-laser IOP. Future prospective studies are needed to evaluate the change in IOP without prophylactic treatment of Nd:YAG lasers.

Intravenous Immunoglobulin (IVIg) in the treatment of refractory ocular cicatricial pemphigoid (OCP)

Peter Chang, MD

Purpose: To examine the treatment outcomes of IVIg in patients with OCP refractory to conventional immunomodulatory therapies.

Methods: Retrospective case series. The medical records of patients with OCP treated with IVIg, from the New York Eye and Ear Infirmary and the Massachusetts Eye Research and Surgery Institution were reviewed.

Results: A total of 21 patients with refractory OCP were included. Mean age of disease onset was 67 years. Patients were previously treated with dapsone (13 of 21), methotrexate (8), mycophenolatemofetil (4), azathioprine (6), cytoxan (10), cytosine arabinoside (2), infliximab (2). Two patients received IVIg as first-line therapy for their OCP because of concurrent atopic ocular and systemic disease. Mean duration of disease prior to IVIg was 21 months. Mean duration of IVIg therapy was 34 months. Mean follow-up time was 58 months. In terms of treatment outcomes, 9 patients (43%) had resolution of conjunctival inflammation and improvement/stabilization of visual acuity while they continued to receive IVIg at last follow-up visit. 6 other patients (29%) remained in remission after stopping IVIg. IVIg was discontinued in 1 patient (4.5%) due to severe pancytopenia. Five patients (24%) failed to respond to IVIg: 3 of these had progression of inflammation and became bilaterally blind, while 2 other required addition of rituximab for OCP control.

Conclusion: IVIg was safe and effective in three quarters of the study population. It should be considered a treatment option in patients with refractory OCP or those who are unable to tolerate other immunomodulatory medications.

Retained Nuclear Fragments in the Anterior Vitreous after Routine Phacoemulsification

Author: Travis Jenkins, MD, Richard Koplun, MD and Elaine Wu, MD

Purpose: To evaluate the incidence of retained nuclear fragments in the anterior vitreous during routine phacoemulsification and to identify risk factors and associated clinical outcomes.

Methods: A retrospective chart review of 100 consecutive cases of uncomplicated phacoemulsification performed by a single surgeon (RSK) was completed. All cases were performed using the Zeiss OPMI Lumera© operating microscope. The occurrence of retained nuclear fragments in the anterior vitreous was recorded. Patient factors including demographics, history of diabetes, glaucoma, shallow anterior chamber depth, alpha-adrenergic blocker use, pseudoexfoliation, perioperative miosis, cataract grade and axial length were evaluated as risk factors. Patients with previous intraocular surgery, significant trauma, phacodonesis or zonular weakness, and retinal diseases were excluded.

Results: Twenty-four of the 100 phacoemulsification cases (24%) demonstrated retained lens fragment(s) in the anterior vitreous intraoperatively. Mean age of patients was 76 years (range 58-93 years). Advanced age and pseudoexfoliation were significantly associated with development of retained nuclear fragments ($p < 0.05$). Gender, presence of pre-existing diabetes, history of glaucoma, shallow anterior chamber depth, alpha-adrenergic blocker use, miosis, cataract grade and axial length did not influence the development of retained nuclear fragments.

Conclusion: Retained nuclear fragment is noted in a significant number of uncomplicated phacoemulsification cases. This phenomenon has been only minimally reported in the literature, and the associated clinical consequences, if any, are unknown. Increasing age and the presence of pseudoexfoliation emerged as associated risk factors. A large prospective study is underway to evaluate whether presence of retained nuclear fragments is associated with increased postoperative adverse events such as cystoid macular edema.

Risk Factors for Intra-operative Complications in Resident Performed Phacoemulsification Cataract Surgery at the New York Eye and Ear Infirmary

Alice Hong MD, Anthony Guan BS, David Ritterband MD; Department of Ophthalmology, The New York Eye and Ear Infirmary, New York, NY; Department of Ophthalmology, New York Medical College, Valhalla, NY

Purpose: To identify risk factors for intraoperative complications in resident performed cataract surgery by phacoemulsification at the New York Eye and Ear Infirmary.

Methods: All eligible patients status post phacoemulsification cataract surgery performed by third year residents at the New York Eye and Ear Infirmary were retrospectively reviewed. The following pre-operative clinical characteristics were obtained: age, sex, history of diabetes, hypertension, blood-thinner use (aspirin, Plavix, Coumadin) or Flomax, history of trauma or prior ophthalmic surgery, pre-operative visual acuity, type of cataract (nuclear sclerotic, posterior capsular, white/mature), presence of pseudoexfoliation and axial length. Intra-operative data obtained included operated eye, type of anesthesia (topical, retrobulbar/peribulbar, general), floppy iris, small pupil, zonular dehiscence, posterior capsular rupture, vitreous loss and dropped nucleus. Post-operative visual acuity was also obtained.

Results: Of 325 patients meeting inclusion criteria 158/325 (48.6%) were female, 167/325 (51.4%) were male. 39/325 (12%) were younger than 50 years old, 217/325 (67%) were between the ages of 51-74. 68/325 (21%) were 75 years and older. 146/325 (44.9%) of the cases were performed by third year residents in the first six months of residency and 179/325 (55.1%) were done in the second half of training. 155/325(47.7%) were right eyes, 170/325 (52.3%) were left eyes. There were 34/325 (10.5%) posterior capsular ruptures, 26/325 (8.0 %) vitreous loss, 12/325 (3.7%) dropped nuclei.

Significant risk factors of posterior capsular rupture included older age ($P=.014$, OR, 1.044; 95% CI 1.009-1.081), white cataracts ($P=.005$, OR, 4.664; 95% CI 1.60-13.58), pseudoexfoliation ($P=.056$, OR, 5.736; 95% CI .954-34.49), history of trauma ($P=.019$, OR 4.452, 95% CI 1.27-15.52) and prior history of pars plana vitrectomy ($P=.000$, OR 7.808, 95% CI 2.82-.59).

Significant risk factors for vitreous loss were similarly older age ($P=0.44$, OR, 1.040; 95% CI 1.00-1.08), white cataract ($P=.003$, OR, 5.490; 95% CI 1.77-16.95), pseudoexfoliation ($P=.024$, OR, 8.076; 95% CI 1.31-49.73), history of trauma ($P=.034$, OR 4.268; 95% CI 1.11-16.38) and prior history of pars plana vitrectomy ($P=.003$, OR 5.790; 95% CI 1.84-18.21).

Significant risk factors for a dropped nucleus older age ($P=.087$, OR, 1.052; 95% CI .993-1.115), white cataract ($P=.024$, OR 6.046; 95% CI 1.26-28.99) and prior history of pars plana vitrectomy ($P=.000$, OR 13.155, 95% CI 3.316-55.194).

Conclusions: Clinical characteristics obtained from the pre-operative history and examination can identify patients at higher risk for intra-operative complications during resident performed phacoemulsification surgery.

Retinal Oximetry in Diabetic Retinopathy

Author Block: Anu Patel, MD

Purpose: To evaluate retinal venous oxygen saturation (SvO₂) in subjects with nonproliferative diabetic retinopathy (NPDR), proliferative diabetic retinopathy (PDR), and non-diabetics.

Methods: Retinal oximetry was performed on 68 subjects (Oxymapeph, Iceland). Oxygen saturation was measured via dual wavelength light absorbance comparison along primary venules and Oxymap software analysis.

Results: Mean SvO₂ in 30 PDR subjects was $73.8 \pm 4.0\%$, 19 NPDR subjects was $58.6 \pm 4.8\%$, and 19 non-diabetics was $61.5 \pm 7.4\%$. Comparing mean SvO₂ in subjects with PDR versus NPDR, $p < 0.0001$, and in subjects with NPDR versus non-diabetics, $p = 0.17$.

Conclusion: Mean SvO₂ is significantly higher in PDR than NPDR. Monitoring SvO₂ via retinal oximetry is a novel, noninvasive alternative to fluorescein angiography to assess disease progression.

Detection of herpes simplex virus-1 (HSV-1) in failed Descemet's stripping automated endothelial keratoplasty (DSAEK) grafts by real-time polymerase chain reaction (PCR)

Dan Yin, M.D.,¹ Andrew Huang, M.D.,¹ David C. Ritterband, M.D.,¹ John A. Seedor, M.D.,¹ Tatyana Milman, M.D.,¹
¹Dept. of Ophthalmology, New York Eye and Ear Infirmary

Purpose: To determine the prevalence of HSV-1 DNA in failed DSAEK grafts and to describe the clinicopathologic findings.

Methods: A retrospective interventional case series of patients with failed DSAEK grafts treated at the New York Eye and Ear Infirmary between January 2009 and June 2011 was performed. Repeat DSAEK or penetrating keratoplasty (PK) were performed on eyes with failed grafts. All failed grafts were examined immunohistochemically and with qualitative real-time PCR for presence of HSV-1 DNA. Corneoscleral donor rims from original DSAEK procedures were examined immunohistochemically and with real-time polymerase chain reaction (PCR) in HSV-1 positive DSAEK grafts.

Results: This study included 35 eyes of 35 patients with failed DSAEK grafts. Indications for DSAEK were pseudophakic bullous keratopathy in 18 eyes (51.4%), Fuchs endothelial dystrophy in 11 eyes (31.4%), PK in 4 eyes (11.4%) and cornea decompensation in 2 eyes (5.7%). Twenty-eight eyes (80%) had primary DSAEK graft failure. Graft rejection, HSV infection and secondary graft failure due to corneal decompensation were responsible for the remaining 7 DSAEK failures. Of the 35 paraffin-embedded tissues submitted for PCR analysis, HSV-1 DNA was isolated from one failed DSAEK graft (2.9%), managed with PK following clinically suspected herpetic keratitis. Histopathologic evaluation showed moderate subacute inflammatory infiltrate in both explanted donor and recipient lenticles. Immunoreactivity for HSV-1 antigen was present both in the recipient cornea and donor DSAEK lenticle, but not in the corneoscleral rim, consistent with reactivation of HSV-1 from the recipient's cornea.

Conclusion: Our data suggests that HSV-1 infection plays a minor role in DSAEK failure. This contrasts with a prior study reporting 33% rate of HSV-1 DNA isolation in failed PK grafts. The much lower rate of HSV-1 infection in failed DSAEK grafts may reflect the less invasive nature of surgical technique as compared to PK and decreased dose/duration of immunosuppressive medications. Histopathologic, immunohistochemical and molecular studies on the single case of HSV-positive failed lenticle and corresponding corneoscleral rim suggest that reactivation from the recipient, rather than donor transmission, was responsible for HSV infection. Additional prospective studies with a larger patient pool should be performed to further examine the role of HSV reactivation in DSAEK failure.

Geo-mapping Direct Animal and Insect Attacks Affecting the Eye using Google Earth, a Feasibility Study looking at Geographic Information Systems in Ophthalmology

Omar Ozgur, MD, Paul Latkany, MD

Department of Ophthalmology, The New York Eye and Ear Infirmary, New York, NY

Background: New and emerging technology has provided many free and useful resources to the medical community. The medical community has successfully utilized geographic information systems (GIS) in epidemiologic research. GIS has helped determine the intersection of disease and geography and helped plan for improved outcomes. However, the data regarding animal and insect bites has been notoriously under reported.

Purpose: To demonstrate the feasibility and usefulness of Google Earth by using free online tools, the authors demonstrate the ability to graphically map cases of direct animal and insect attacks affecting the eye. Our primary outcome is to measure the number of cases that have detailed geospatial data to construct a comprehensive meta-analysis.

Primary outcome: No geospatial data was provided to permit a comprehensive meta-analysis of ocular injury regarding the eye.

Methods: A PubMed search using the text “(insect OR bug OR animal) AND (bite OR sting OR attack) AND (eye OR ophthalmology OR conjunctiva OR orbit OR eyelid)” was done to find all cases of animal attacks or insect stings reported in PubMed. This list was exported to an XML file. A free software program pubmed2xl <http://blog.humaneguitarist.org/projects/pubmed2xl/> was used to convert this XML file to a Microsoft Excel file. The list was filtered to include only appropriate articles with adequate geographic data. This included 174 articles comprising 266 cases. Information in PubMed is available only with the authors’ affiliation information, usually providing a city, state, and/or zip code. The next step involved geocoding the available address data for each article into a latitude and longitude, as Google Earth accepts location information in latitude and longitude only. The authors made use of an available spreadsheet(GoogleMapping.xlsm) at <http://ramblings.mcpher.com/Home/excelquirks/downloadlist> to do this. This information, along with the output from PubMed was inputted into another free tool (XLS2KML.xls) at <http://freegeographytools.com/2007/xls2kml-another-excel-to-kml-converter-with-a-few-extras>), which we modified to suit our needs. The output from this tool is a KML file which can be directly opened using Google Earth (<http://www.google.com/earth/>).

When the KML file is opened, along the left side of Google Earth, an option is available to display Animal attack and insect sting information. When these selections are made, a corresponding icon(dog, larva or bee icon) is placed in the appropriate geographic location on the main Google Earth screen. A user can navigate around the globe to find locations in which animal attacks or insect stings have been reported while making use of all the tools Google makes available including zooming in and out among many other.

Of note, in cases when more than one incident was reported, the corresponding icon in the main screen is made larger. When a user clicks an icon, a window will pop-up, showing all the information available from PubMed including the PubMed ID, Author(s), Title, Abstract, Publication year and Journal title.

Results: Of 117 reported direct animal attacks to the eye with enough information to map, dog attacks represent 50% of cases, snake attacks represent 24%, bird attacks 7%, and others are 19% consisting of human, jellyfish, cat, rat, fox, and jellyfish attacks. Countries reporting the most animal attack injuries to the eye include the United States with 55% of cases, Australia with 10%, and India with 6% of cases. Other countries and regions which reported animal injuries represent 29% of cases and include Austria, Brazil, Canada, Colombia, Germany, Israel, Japan, Morocco, Nepal, Nigeria, Poland, Saudi Arabia, Serbia, Singapore, South Africa, South Korea, Switzerland, Taiwan, Turkey, and the United Kingdom.

Of 149 reported direct insect attacks to the eye with enough information to map, myiasis represent 63% of cases, bee and wasp attacks represent 23%, tick attacks 4%, and others are 10% consisting of ant, beetle, caterpillar, mosquito, sand fly, scorpion, spider, walking stick, worm, and unspecified insect cases. Countries reporting most direct insect attack injuries to the eye include the United States with 14% of cases, Jordan with 11%, and Tunisia with 8%. Other countries and regions which reported insect injuries represent 67% of cases and include Argentina, Australia, Brazil, Canada, China, Cyprus, Czech Republic, Denmark, Egypt, France, French Guiana, Germany, Hong Kong, India, Indonesia, Iran, Iraq, Israel, Italy, Japan, Kuwait, Lebanon, New Zealand, North Africa, Pakistan, Poland, Saudi Arabia, Singapore, Slovakia, South Korea, Spain, Sri Lanka, Taiwan, Thailand, The Netherlands, Turkey, and the United Kingdom.

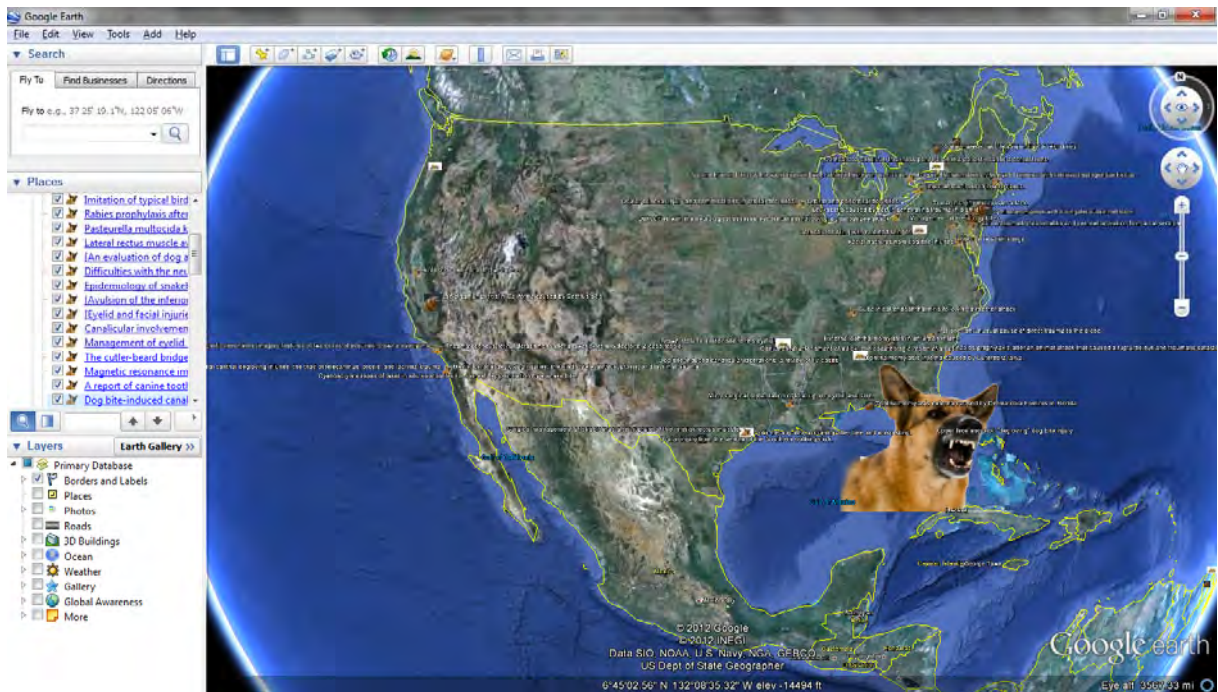


Fig. 1. Displaying Google Earth with Animal and Insect Attack data.

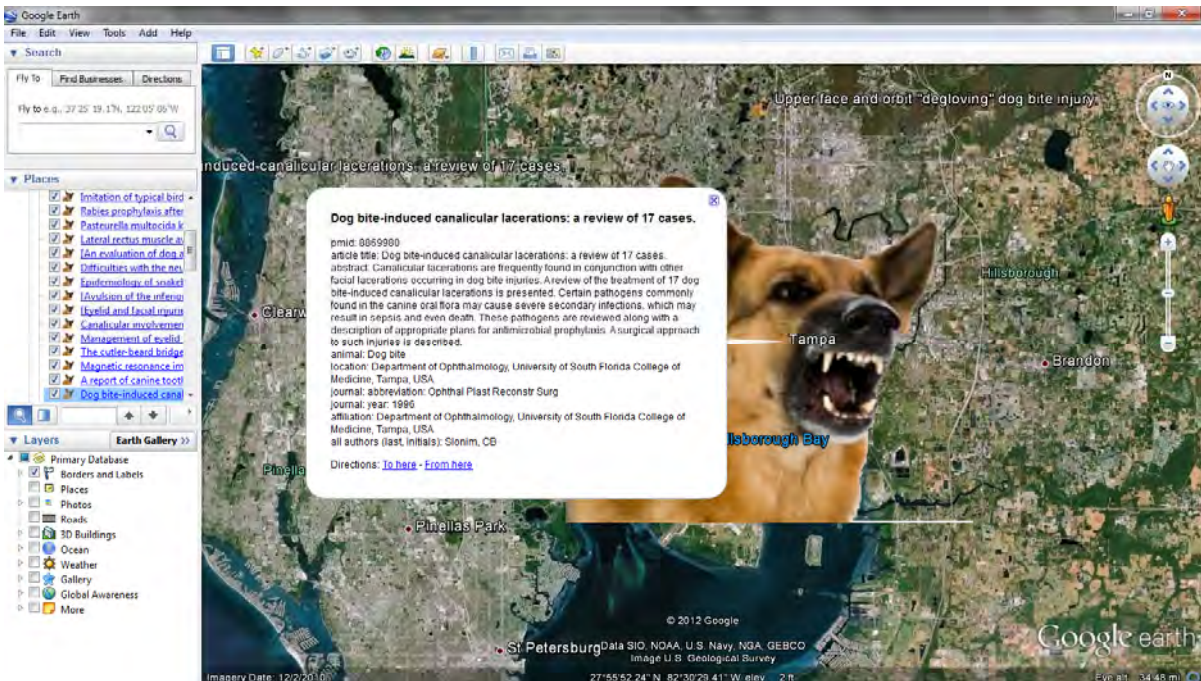


Fig. 2. Displaying Google Earth with Animal and Insect Attack data focusing on a specific report by clinic the representative icon. Information from PubMed is displayed in the pop-up window.

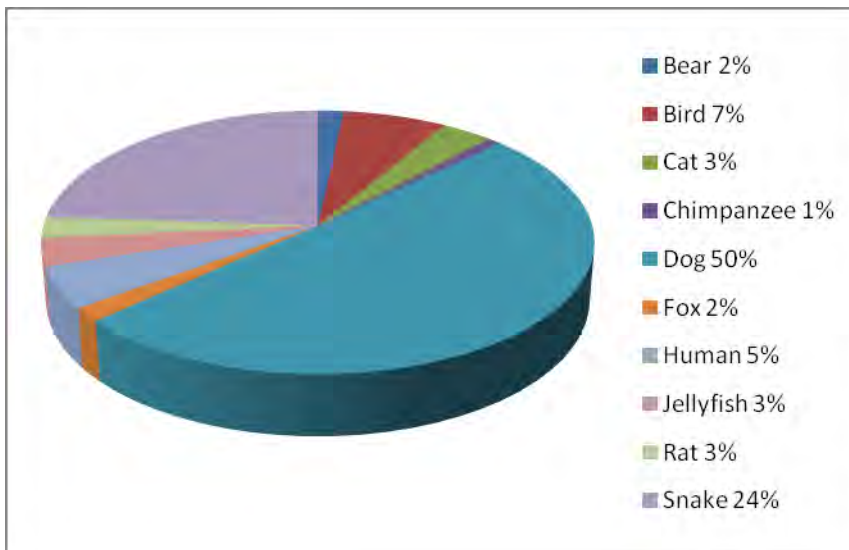


Fig. 3. Graph displaying reported direct Animal attacks to the eye by animal type.

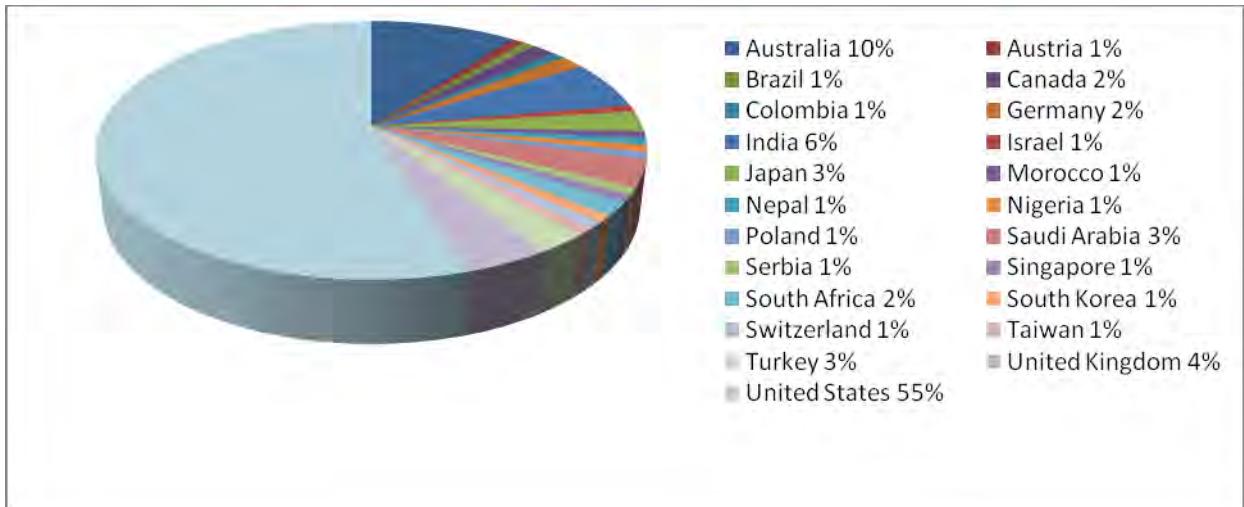


Fig. 4. Graph displaying reported direct Animal attacks to the eye by country or region.

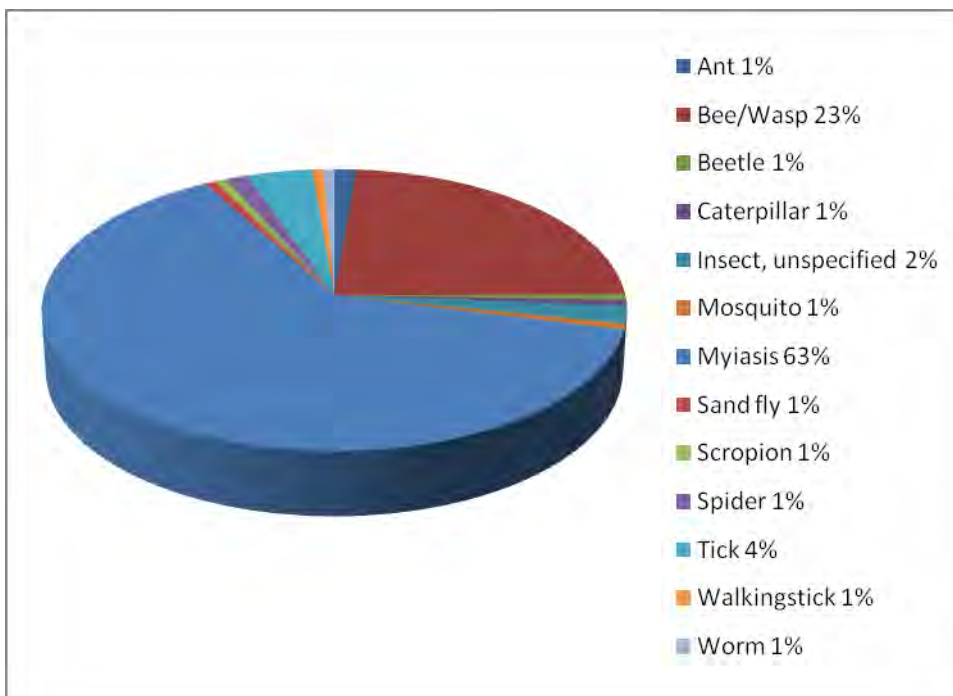


Fig. 5. Graph displaying reported direct Insect attacks to the eye by insect type.

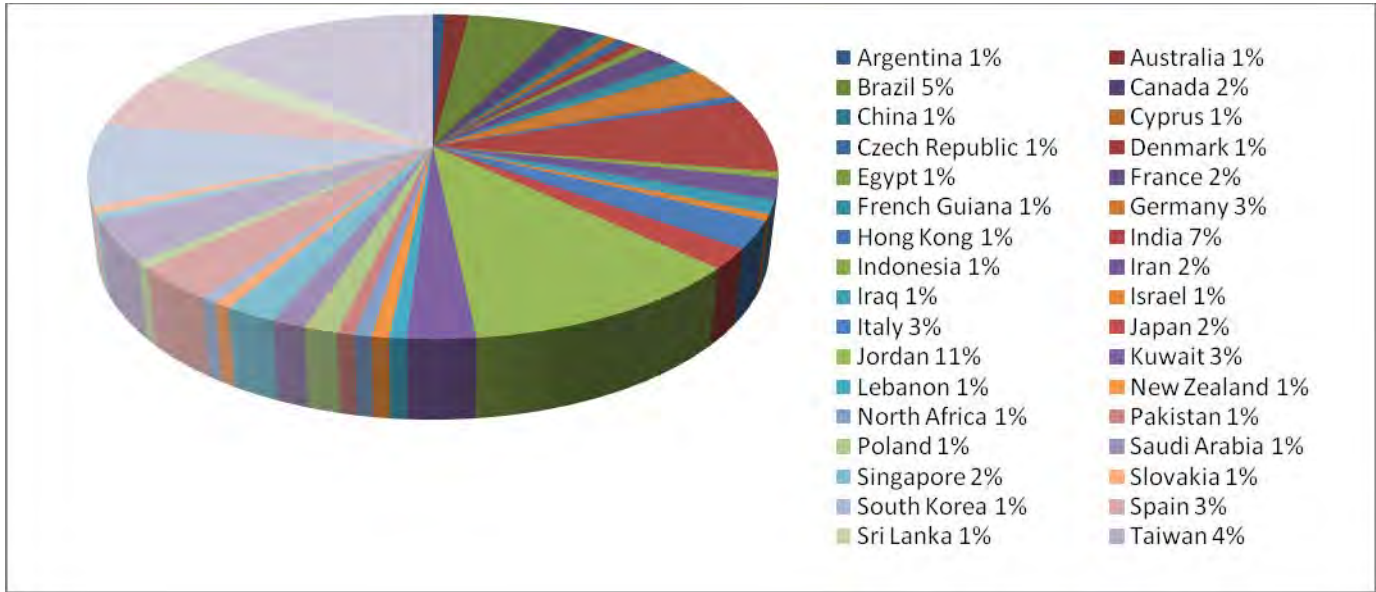


Fig. 6. Graph displaying reported direct Insect attacks to the eye by country or region.

Conclusions: Our demonstration shows that GIS integration can be useful to the analysis of ocular bite injury and can be made simply and at minimum cost. However, the current reporting of geospatial data regarding animal and insect bite-related ocular injury to the eye is poor and requires further standardization.

Commercial Relationships: None

Risk Factors for Retinal Neovascularization in Patients with Uveitis

Authors/Affiliations: Apurva K. Patel,^{1A,2} Craig Newcomb, MS,^{1B} Teresa L. Liesegang, COT, CRC,^{2A} Siddharth S. Pujari, MBBS, MS(Oph), MPH,^{3,4} Eric B. Suhler, MD, MPH,^{2A,5} Jennifer E. Thorne, MD, PhD,^{6A,B} C. Stephen Foster, MD,^{4,7} Douglas A. Jabs, MD, MBA,^{6A,B,8A,B} Grace A. Levy-Clarke, MD,^{9,10} Robert B. Nussenblatt, MD, MPH,⁹ James T. Rosenbaum, MD,^{2A,B} and John H. Kempen, MD, PhD,^{1A-C}

^AOphthalmology, ^BBiostatistics& Epidemiology, ^COcular Inflammation Service ¹University of Pennsylvania / Scheie Eye Institute, Philadelphia, Pennsylvania; ²Ophthalmology, New York Eye and Ear Infirmary, New York, New York; ^AOphthalmology, ^BInternal Medicine; ³Casey Eye Institute-Oregon Health Sciences University, Portland, Oregon; ⁴LIONS NAB Eye Hospital, Miraj, Maharastra, India; ⁵Massachusetts Eye Research and Surgery Institution, Cambridge, Massachusetts; ⁶Portland Veterans Affairs Medical Center, Portland, Oregon; ^AOphthalmology and ^BEpidemiology, ⁷Johns Hopkins Wilmer Eye Inst, Baltimore, Maryland; ⁸Ophthalmology, Harvard Medical School, Boston, Massachusetts, ^AOphthalmology and ^BMedicine, ⁹Mount Sinai School of Medicine, New York, New York, ¹⁰National Eye Inst/NIH, Bethesda, Maryland; ¹¹St Lukes Cataract and Laser Institute, St Petersburg, Florida

Abstract:

Purpose: To evaluate the risk of retinal neovascularization (NV) in patients with uveitis and evaluate potential risk factors and associated features.

Methods: Retrospective cohort study of patients with uveitis at five academic ocular inflammation subspecialty practices. Data were ascertained by standardized chart review. Incidence data were analyzed using survival analysis with time-updated covariates where appropriate.

Results: 95/8771 patients presenting for initial evaluation had NV giving a prevalence of 1.1%. 79 patients developed NV over 15,523 person-years for an incidence of 0.51% per person-year. Factors associated with incident NV include age <35 as compared to >35 years (adjusted hazard ratio (HR) = 2.2, 95% confidence interval 1.4-3.6), systemic hypertension (1.8;1.1-3.0), current cigarette smoking (2.2;1.3-3.7) and diagnosis of uveitis within the last 5 years as compared to >5 years (2.2;1.1-4.2). As compared to anterior uveitis, intermediate uveitis carried an adjusted HR of 3.5 (1.7-7.0), posterior uveitis 4.0 (2.0-8.2), and panuveitis 4.1 (2.0-8.6). NV was associated with retinal vascular occlusions (7.7;2.3-26), retinal vascular sheathing (2.3;1.3-4.4), and exudative retinal detachment (3.7;1.1-12). Systemic lupus erythematosus also was associated with NV (3.4;1.3-10). Currently active inflammation was weakly associated as compared to inactive inflammation (crude HR 1.6;0.95-2.6) however in the adjusted analysis this association was not significant (adjusted HR 1.1; 0.66-1.8). The association was stronger in the prevalence analysis (adjusted odds ratio 2.2; 1.1-4.3).

Conclusions: Retinal NV is a rare complication of uveitis, which occurs more frequently in patients with posterior disease, systemic vasculopathy and retinal vascular disease. Concurrent active inflammation was associated with prevalent NV more than with incident NV. This suggests that NV is a long-term rather than short-term complication of intraocular inflammation.

Endocrine Mucin-Producing Sweat Gland Carcinoma of the Eyelid: Diagnostic and Prognostic Considerations

Ambika Hoguet, MD, Tatyana Milman, MD, Steven McCormick, MD, Elizabeth Maher, MD, Robert Della Roca, MD, David Della Roca, MD, David Warrow, MD, Andrew Goldbaum, MD, James Milite, MD

Purpose: To describe the characteristics of mucin-producing sweat gland carcinoma (MPSGC) and to determine whether endocrine differentiation is of prognostic significance.

Methods: The medical records of all patients diagnosed with MPSGC between 1990 and 2011 at the New York Eye and Ear Infirmary were reviewed. Clinical data collected included patient demographics, tumor location and appearance, adequacy of surgical excision, recurrence and metastasis. Histopathology and immunohistochemistry were reviewed, including tumor morphology, in-situ vs. invasive distribution (based in part on immunostaining for myoepithelial markers smooth muscle actin and p63), evidence of apocrine differentiation (BRST-2, estrogen and progesterone receptors), mitotic index (ki-67), and neuroendocrine differentiation (neuron-specific enolase, synaptophysin, chromogranin and CD56).

Results: 17 eyes of 17 patients were identified. The mean age at diagnosis was 70 years (range 53-87), with 64% (11/17) male and 35% (6/17) female patients. 35%(6/17) of lesions were located on the lower lid and 53% (9/17) on the upper lid. All tumors were excised initially with positive margins. Re-excision for margin clearance was performed in 8/17 cases. The mean follow-up period was 20 months (range 4 days – 82 months). Histopathologic and immunohistochemical evaluation showed that 5/16 of tumors were in situ, 6/16 invasive, and 5/16 demonstrated both growth patterns. All tumors showed apocrine differentiation and had ki-67 proliferative index of 3-5%. All tumors showed focal positivity for at least ¼ neuroendocrine markers. Recurrence was noted in one two lesions—one with an in situ component and one with an invasive component—at 3 years and at 10 months respectively, despite pathologically confirmed clearance of surgical margins. Recurrent tumor had histopathologic and immunohistochemical characteristics identical to the primary lesion. None of the patients developed regional or distal metastases.

Conclusions: MPSGC is a rare tumor which pathologically presents as a continuum, from an in situ lesion with hydrocystoma-like appearance to classic, invasive carcinoma nests floating in pools of mucin. An invasive component is not necessary for recurrence to occur and all cases of MPSGC should be closely monitored for the possibility of recurrence. Endocrine differentiation can be observed in all lesions and does not appear to have a prognostic significance, arguing against utility of immunohistochemical sub-typing of MPSGC.

Acetazolamide for the Management of Uveitic Macular Edema

Joseph Tseng, MD, C. Michael Samson, MD

Purpose: This report describes the effect of the systemic carbonic hydrase inhibitor acetazolamide on patients with inflammatory macular edema unresponsive to other treatment strategies.

Methods: We retrospectively identified and evaluated **NUMBER** of patients with inflammatory eye disease, who were subsequently noted to develop intraretinal macular edema (ME) that did not respond to conventional treatment with topical, periorcular, or systemic corticosteroid treatment or topical non-steroidal anti-inflammatory drugs (NSAIDs). Treatment response was evaluated by spectral domain optical coherence tomography (SD-OCT) at 1 month and 3 months intervals. Additional evaluation included fluorescein angiography where indicated.

Results: In all, **NUMBER** of eyes with recalcitrant ME were identified and treated with acetazolamide 500 mg 3 times daily. Initial mean best-corrected visual acuity (BCVA) was **NUMBER**logMAR (approximately **NUMBER** by Snellen acuity). All eyes showed evidence of improvement of acetazolamide by SD-OCT at 1 month follow-up, with **NUMBER** of eyes maintaining or furthering this improvement at 3 months. The mean final BCVA was **NUMBER** logMAR (approximately **NUMBER**Snellen acuity).

Conclusion: Treatment with acetazolamide may achieve improvement and/or resolution of inflammatory ME that does not respond to treatment with corticosteroids or NSAID. Larger comparative or prospective studies are required to evaluate this treatment modality in comparison to other strategies, including treatment with anti-vascular endothelial growth factor (VEGF) agents.

Adult Tearing Patients Managed Successfully With Primary Monocanalicular Intubation: Follow-up Study

Authors: Y Kashyap MD, S Lauer M.D.

Introduction: Studies on primary nasolacrimal intubation for adult patients with acquired nasolacrimal duct obstruction have reported improvement or resolution of symptoms in 52-80% of patients. Bicanalicular intubation with stents such as the Crawford, Guibor or Ritleng tubes is limited by the need for retrieval of probes or guide wires through the nasal passage. In contrast, monocanalicular intubation can be performed under local anesthesia without manipulation of the nasal passage. We sought to study the long-term efficacy of monocanalicular intubation following probe and irrigation of the nasolacrimal system performed on adults with primary lacrimal system obstruction under local anesthesia.

Methods: Patients who underwent primary monocanalicular intubation, for partial or complete dacryostenosis confirmed with office irrigation, were surveyed twelve or more months following the procedure regarding the status of their epiphora. The procedures were all performed under local anesthesia and stents were removed after four weeks. Epiphora was graded on a four point scale, measured prior to the procedure, 3 months following the procedure and at last follow-up (grade 1: complete resolution, grade 2: minimal tearing, not bothersome, grade 3: improvement but still bothersome tearing, grade 4: no improvement post procedure, persistent tearing).

Results: Of the 77 eyes in 56 patients treated with primary monocanalicular intubation reliable data could be obtained more than 18 months after the procedure in 58 eyes in 40 patients (16 patients were deceased or lost to follow up). The mean age was 72.6 ± 10.3 years, 47.5% male gender and 52.5% female, mean follow up was 24.4 months (range 18-34 months). All surveyed patients reported grade 3 or 4 epiphora prior to the procedure. Resolution defined as grade 1 or 2 epiphora at six months was reported by 41/58 patients (70%). Among patients who reported resolution of epiphora, 40/41 (97.6%) reported continued resolution of epiphora at the last follow-up. Of 17/58 (30%) who had persistent epiphora 4/17 (23.5%) underwent a dacryocystorhinostomy.

Conclusions: Monocanalicular stenting is an efficacious and minimally invasive treatment for epiphora and dacryostenosis. As in the pediatric population, canalicular intubation is far from a replacement for DCR, but rather it spares the morbidity of DCR for those that can improve with office intubation under local anesthesia.

Pars Plana Baerveldt Implantation for Refractory Childhood Glaucomas: A Follow-up Study

Kateki Vinod, MD, Paul Sidoti, MD

PURPOSE: The purpose of this study is to assess the long-term efficacy and complication profile associated with Baerveldt glaucoma implant surgery with pars plana tube insertion in aphakic and pseudophakic children with refractory glaucoma. This is a follow-up to a previous retrospective study conducted at NYEEI (Banitt et al. Pars Plana Baerveldt Implantation for Refractory Childhood Glaucomas. *J Glaucoma* 2009;18:412-7).

METHODS: This is a retrospective review of the charts of the thirty patients included in the original study. The patients are aphakic or pseudophakic children less than eighteen years old with uncontrolled glaucoma who underwent PPBGI between January 1990 and January 2005. Clinical outcomes include intraocular pressure, visual acuity, number of intraocular pressure-lowering medications, and postoperative complications. Success was defined in the original study as final postoperative IOP between 5 and 21 mmHg with or without intraocular pressure-lowering medications, and without visually devastating complications or additional glaucoma surgery.

RESULTS: In the original study, mean postoperative follow-up was 29.8 +/- 26.4 months. Successful intraocular pressure control was achieved in 85%, 81%, and 72% of patients at 12, 24, and 36 months. Postoperative complications included hypotony, retinal detachment, tube obstruction, pupillary membrane, worsening esotropia, and focal sclera ectasia. Three patients had visually devastating complications such as loss of light perception, hemorrhagic choroidals, and phthisis. Preliminary results in the current study show a mean postoperative follow-up of 105.6 +/- 30.3 months among 8 of the 30 patients. Mean postoperative IOP at most recent follow-up was 19.5 +/- 7.5 mmHg, and mean number of glaucoma medications was 1.67 +/- 1.5. Five of 8 patients had a successful outcome based on IOP control at the time of most recent follow-up. One patient required repeat PPV & BGI revision for tube obstruction but achieved IOP control at most recent follow-up, and 2 developed retinal detachment requiring repair, but achieved IOP control at most recent follow-up. 3 of 8 patients are considered failures; 2 did not achieve IOP control at the time of most recent follow-up, and 1 lost light perception at 90 months.

CONCLUSIONS: This study is ongoing and additional follow-up data are currently being collected and analyzed.

Enhanced Depth Imaging Optical Coherence Tomography of Central Optic Disc Pits

Authors: Timothy Sullivan, MD; Sung Chul Park, MD; Shehzad Qayum, MD; Rudrani Banik, MD; Jeffrey M. Liebmann, MD; Robert Ritch, MD

Purpose: To assess lamina cribrosa (LC) structure in eyes with a clinically observed central optic disc pit (ODP) using enhanced depth imaging optical coherence tomography (EDI OCT).

Methods: Subjects with a centrally located ODP (Fig. A and F) and normal subjects were prospectively enrolled. For each eye, full ophthalmological examinations were performed including optic disc stereophotography, standard automated perimetry, and circumpapillary OCT retinal nerve fiber layer (RNFL) thickness measurement. Serial horizontal and vertical EDI OCT scans of the optic nerve head covering the central ODP area (interval between scans: approximately 30 μm) were obtained for each eye and reviewed to assess the structure of the central ODP, focusing on the LC. Spatial relationships between the central ODP and the central retinal vascular trunk (CRVT) were also investigated.

Results: Fifteen eyes of 10 subjects with a central ODP (mean age: 63 \pm 20 yr) and 60 eyes of 30 normal subjects (mean age: 43 \pm 13 years) were included. In all 15 affected eyes, the central ODP corresponded to a full-thickness defect of the LC in EDI OCT scans, and these LC defects varied in size and shape. No such finding was detected in the normal group. In 9 affected eyes, the LC defects were completely separated by LC tissue from the LC opening for the CRVT (type 1). In the remaining 6 eyes, the LC defects were continuous with the LC opening for the CRVT, forming a large, horizontally oval opening (type 2). Ten out of 15 affected eyes (66%; five with type 1 central ODP and five with type 2 central ODP) had glaucoma. The remaining 5 affected eyes were normal, with no visual field or RNFL defects.

Conclusions: Central ODPs corresponded to full-thickness defects of the LC and can be classified into 2 types depending on their spatial relationship to the LC opening for the CRVT. The presence of normal eyes with a central ODP suggests its congenital etiology.

Macular Leakage and Peripheral Vascular Leakage on Ultra-Wide Field Fluorescein Angiography

Ella Leung, MD

Purpose: To determine the relationship between leakage in the macula and peripheral vascular leakage in the mid-peripheral and far peripheral retina using ultra-wide field fluorescein angiography.

Methods: The ultra wide field fluorescein angiographies of 212 eyes in 136 patients with macular leakage were analyzed. Of the 189 eyes with OCTs, cystoid macular edema (CME) was confirmed in 156 eyes of 100 patients. The severity of macular leakage and the severity of leakage in the central 55 degrees of the retina and the far periphery/ anterior retina were measured.

Results: The most common past ocular histories for patients with cystoid macular edema (CME) were proliferative diabetic retinopathy (75%), central and branch retinal vein occlusion (10%), uveitis (9%), and age-related macular degeneration (5%). The majority of eyes with macular leakage on FA and CME confirmed on OCT had fluorescein leakage in the peripheral retina. Twenty eyes (13%) had greater leakage in the far periphery than in the posterior pole, and 58% of eyes had bilateral leakage in the macula. Although 91% of eyes had some degree of leakage in the peripheral retina, the linear logistic regression coefficients for CME and central 55° were 0.274 ($|p|>z= 0.104$), CME and far peripheral leakage -0.124 ($|p|>z= 0.946$), CME and central 55° with a history of laser -0.335 ($|p|>z= 0.315$), and CME and far peripheral leakage with a history of laser -0.812 ($|p|>z= 0.039$).

Conclusions: In patients with leakage in the macula, there is a high incidence of peripheral leakage; however, there is no direct correlation between the severity of leakage in the macula and the peripheral retina. Ultra- wide field angiograms are useful for detecting far peripheral leakage and may provide an earlier indication laser photocoagulation.

Analysis of Refractive Outcomes of Secondary Intraocular Lens Placement in a Tertiary Referral Center

Wendy W Huang MD, Ben Bert MD, Jocelyn Kuryan MD, Omar Ozgur MD, Elaine Wu MD, David C Ritterband MD, John A Seedor MD

Purpose: Secondary intraocular lenses (IOLs) are now an accepted and widely popular alternative to anterior chamber intraocular lenses.¹² There are several methods of securing secondary IOLs including iris fixation and scleral fixation. From our previous analysis, suturing secondary IOLs showed low complication rates and were a good option when capsular support does not exist. Given the possibility of optic tilt with sutured fixation and limitations of biometry, our study attempts to characterize the refractive outcomes of secondary IOL placement.

Methods: Retrospective review of inserted secondary IOLs at a tertiary referral center spanning a 4 year period. Cases were reviewed between October 2006 to 2010. Scleral fixated and iris fixated intraocular lenses were inserted by two surgeons at a tertiary referral center. All eyes requiring penetrating keratoplasty were excluded from our analysis. Predicted spherical refractive outcome was compared to postsurgical outcome.

Results: We found that 60% (48) were myopic by spherical equivalent relative to the predicted refraction and 40% (32) were hyperopic. 17.5% (14) of eyes achieved refractions deviating less than or equal to 0.50 diopters from predicted outcomes (group 1), 32.5% (26) greater than or equal to 0.50 diopters but less than 1.00 diopter (group 2), and 55% (44) greater than or equal to 1.00 diopters (group 3). Average axial lengths for groups 1, 2, and 3 were 24.14, 24.20, and 24.77 respectively. Axial lengths between the groups were compared using the t-test, none were significantly different from each other with p-values of 0.451 (group 1 and 2), 0.080 (group 2 and 3), and 0.127 (group 1 and 3). Astigmatism was also evaluated. Average astigmatism in groups 1, 2, and 3 were 1.02, 1.04, and 1.88 respectively. No significant difference among the groups by t-test with p-values of 0.238 (group 1 and 2), 0.041 (group 2 and 3), and 0.228 (group 1 and 3).

Conclusions: From our data the majority of patients' postsurgical refractions will deviate greater than 1 diopter from predicted values. It also shows that neither astigmatism nor axial length is a reliable predictive factors for refractive deviation. This may prove useful in counseling patients regarding expectations in refractive error. Our study is limited secondary to small sample size, bias of being a tertiary referral center, and lack of controls. Future comparison of refractive outcomes in iris vs. scleral fixated intraocular lenses may be cogent as well as investigation of lens position.

¹Wagoner MD, Cox TA, Ariyasu RG, Jacobs DS, Karp CL; American Academy of Ophthalmology. Intraocular lens implantation in the absence of capsular support: a report by the American Academy of Ophthalmology. *Ophthalmology*. 2003 Apr;110(4):840-59.

²Bading G, Hillenkamp J, Sachs HG, Gabel VP, Framme C. Long-term safety and functional outcome of combined pars planavitrectomy and scleral-fixated sutured posterior chamber lens implantation. *Am J Ophthalmol*. 2007 Sep;144(3):371-377. Epub 2007 Jul 10.

Focal Lamina Cribrosa Defects and Glaucomatous Visual Field Progression

Omar S. Faridi¹, Sung C. Park^{1,2}, Daniel Su^{1,3}, Joseph Simonson¹, Anthony Hsu¹, Carlos G. De Moreas^{1,4}, Christopher Teng^{1,2}, Celso Tello^{1,2}, Jeffrey M. Liebmann^{4,1}, Robert Ritch^{1,2}.
1Einhorn Clinical Research Center, New York Eye and Ear Infirmary, New York, NY;
2Ophthalmology, New York Medical College, Valhalla, NY; 3Mount Sinai School of Medicine, New York, NY; 4Ophthalmology, NYU School of Medicine, New York, NY.

Abstract:

Purpose: To compare glaucomatous visual field (VF) progression between eyes with and without focal lamina cribrosa (LC) defects.

Methods: Serial horizontal and vertical enhanced depth imaging optical coherence tomography (EDI OCT) B-scans of the optic nerve head (interval between scans: approximately 30 μm) were obtained prospectively from glaucoma patients with 5 or more prior 24-2 VF tests. EDI OCT scans were reviewed for the presence of focal LC defects (focal LC disinsertion or full-thickness LC defect) that violated the smooth curvilinear contour of the normal anterior laminar surface. The maximum width of each focal LC defect was required to be $\geq 100 \mu\text{m}$. Progression rates were calculated using pointwise linear regression (PLR) analysis and averaged to generate the global progression rate (dB/yr) for each eye. VF progression was defined as having ≥ 1 significantly progressing point(s) (slope $< -1.0 \text{ dB/yr}$ at $P < 0.01$). The rates at these points were averaged to generate the localized progression rate (dB/yr) for each eye. Age, intraocular pressure [IOP], baseline visual field [VF] mean deviation [MD], a detected disc hemorrhage, and central corneal thickness [CCT] were recorded.

Results: A total of 104 eyes were included (104 patients; mean age, 66 ± 13 yr; mean baseline VF MD, -10.2 ± 7.6 dB): 45 eyes had focal LC defects and 59 did not (control group). The mean number of VF tests (9.2 vs. 8.8) and follow-up period (6.7 vs. 7.1 yrs) were similar between the two groups (all $P > 0.2$). Significantly more eyes had progressed in the LC defect group than in the control group (27 eyes [61%] vs. 16 eyes [27%]; $P < 0.001$). Mean global (-0.61 vs. -0.22 dB/yr) and localized progression rates (-3.51 vs. -1.96 dB/yr) were significantly greater in eyes with focal LC defects than in those without ($P = 0.015$ and 0.010 , respectively), whereas the mean number of progressing points were similar between the two groups (5.4 vs. 5.1; $P = 0.5$). After adjusting for age, mean follow-up IOP, baseline VF MD, disc hemorrhage detection, and CCT, however, there was a borderline, but non-significant difference between groups regarding global ($P = 0.08$) and localized ($P = 0.16$) progression rates. Among the evaluated parameters, the presence of focal LC defect and number of VF tests were significantly associated with VF progression in both univariate (OR, 4.27; $P < 0.001$ and OR, 1.19; $P = 0.0027$, respectively) and multivariate (OR, 4.87; $P < 0.001$ and OR, 1.20; $P = 0.002$, respectively) logistic regression analyses.

Conclusions: Focal LC defect is highly associated with glaucomatous VF progression. :

Author Disclosure Information: Omar S. Faridi, None; Sung C. Park, None; Daniel Su, None; Joseph Simonson, None; Anthony Hsu, None; Carlos G. De Moreas, None; Christopher Teng, None; Celso Tello, None; Jeffrey M. Liebmann, Carl Zeiss Meditec, Inc (F), Carl Zeiss Meditec, Inc. (C), Heidelberg Engineering, GmbH. (F), Optovue, Inc. (C), Topcon, Inc. (C); Robert Ritch, None **Reviewing Code (Complete):** 202 glaucoma: structure/function relationships - GL **Presentation Preference (Complete):** Paper #1, Poster #2

Keyword (Complete): 626 optic nerve ; 549 imaging/image analysis: clinical ; 754 visual fields
Clinical Trial/Newsorthy (Complete): *Does the research presented in your abstract meet the definition of a clinical trial?: No *Newsorthy: No

Support (Complete): Do you have grant support?: Yes ***Support :** Ettinger Foundation Research Fund of the New York Glaucoma Research Institute, New York, NY. Dr. Park is the Peter Crowley Research Scientist at the New York Eye and Ear Infirmary.

Status: Complete

Risk Factors for Focal Lamina Cribrosa Defects in Glaucoma

Anthony T. Hsu¹, Sung Chul Park^{1,2}, Daniel Su^{1,3}, Joseph Simonson¹, Christopher Teng^{1,2}, Celso Tello^{1,2}, Jeffrey Liebmann^{4,1}, Robert Ritch^{1,2}. 1Einhorn Clinical Research Center, New York Eye and Ear Infirmary, New York, NY; 2Ophthalmology, New York Medical College, Valhalla, NY; 3Mount Sinai School of Medicine, New York, NY; 4Ophthalmology, NYU School of Medicine, New York, NY.

Purpose: To assess risk factors for focal lamina cribrosa (LC) defects in glaucoma detected by enhanced depth imaging optical coherence tomography (EDI OCT).

Methods: Patients with a range of glaucomatous damage were prospectively enrolled and had full eye examinations including serial horizontal and vertical enhanced depth imaging optical coherence tomography (EDI OCT) B-scans of the optic nerve head (interval between scans, approximately 30 μ m). For one randomly selected eye of each patient, EDI OCT scans were reviewed for the presence of focal LC defects (focal LC disinsertion or full-thickness LC defect) that violated the smooth curvilinear contour of the normal anterior laminar surface. The maximum width of each focal LC defect was required to be $\leq 100 \mu$ m. Clinical characteristics (age, central corneal thickness [CCT], visual field [VF] mean deviation [MD], exfoliation syndrome, and disc hemorrhage detection and intraocular pressure [IOP] during past follow-up) were recorded and compared between eyes with and without focal LC defects.

Results: Among 114 eyes included (114 patients; mean age, 64 ± 14 yr; mean VF MD, -9.9 ± 7.7 dB), 50 (44%) eyes had focal LC defects and 64 (56%) did not. The mean follow-up period for IOP and disc hemorrhage data collection was similar between eyes with and without focal LC defects (6.4 ± 4.0 vs. 6.7 ± 3.3 years; $P=0.67$). Eyes with focal LC defects had significantly greater mean follow-up IOP (15.0 vs. 13.5 mmHg), higher disc hemorrhage detection rate (20.5% vs. 6.8%), and worse VF MD (-15.9 vs. -10.2 dB) than those without focal LC defects ($P=0.008$, 0.031 and 0.039 , respectively). Age, CCT and proportion of exfoliation syndrome were similar between the 2 groups (all $P>0.24$). In univariate logistic regression analysis, mean follow-up IOP (OR, 1.14; $P=0.037$), disc hemorrhage detection (OR, 3.54; $P=0.048$), and VF MD (odds ratio [OR], 1.11; $P<0.001$) were significantly associated with the presence of focal LC defects. In multivariate analysis, mean follow-up IOP (OR, 1.18; $P=0.024$), disc hemorrhage detection (OR, 5.07; $P=0.024$), and VF MD (odds ratio [OR], 1.13; $P<0.001$) remained significant factors associated with the presence of focal LC defects.

Conclusions: IOP, disc hemorrhage and disease severity are associated with focal LC defects. Future investigation is needed to elucidate the pathogenetic relationships between focal LC defects and these risk factors.

Author: Disclosure Information: Anthony T. Hsu, None; Sung Chul Park, None; Daniel Su, None; Joseph Simonson, None; Christopher Teng, None; Celso Tello, None; Jeffrey Liebmann, Heidelberg Engineering, GmbH (F), Optovue, Inc. (C), Topcon, Inc. (C); Robert Ritch, None
Reviewing Code (Complete): 202 glaucoma: structure/function relationships – GL Presentation Preference (Complete): Paper #1, Poster #2
Keyword (Complete): 576 lamina cribrosa ; 551 imaging methods (CT, FA, ICG, MRI, OCT, RTA, SLO, ultrasound) ; 464 clinical (human) or

epidemiologic studies: risk factor assessment Clinical Trial/Newsworthy (Complete): *Does the research presented in your abstract meet the definition of a clinical trial?: No

*Newsworthy: No

Support (Complete):

Do you have grant support?: Yes

*Support : Supported by Gloria Rubin Research Fund of the New York Glaucoma Research Institute, New York, NY. Dr Park is the Peter Crowley Research Scientist at the New York Eye and Ear Infirmary.

Status: Complete

Efficacy of the Amsler Grid Test in Evaluating Glaucomatous Central Visual Field Defects

Author Block: Andrew Greenberg¹, Daniel Su^{1,2}, Joseph Simonson¹, Sung Chul Park^{1,3}, Celso Tello^{1,3}, Jeffrey Liebmann^{4,1}, Robert Ritch^{1,3}. ¹Einhorn Clinical Research Center, New York Eye and Ear Infirmary, New York, NY; ²Mount Sinai School of Medicine, New York, NY; ³Ophthalmology, New York Medical College, Valhalla, NY; ⁴Ophthalmology, NYU School of Medicine, New York, NY.

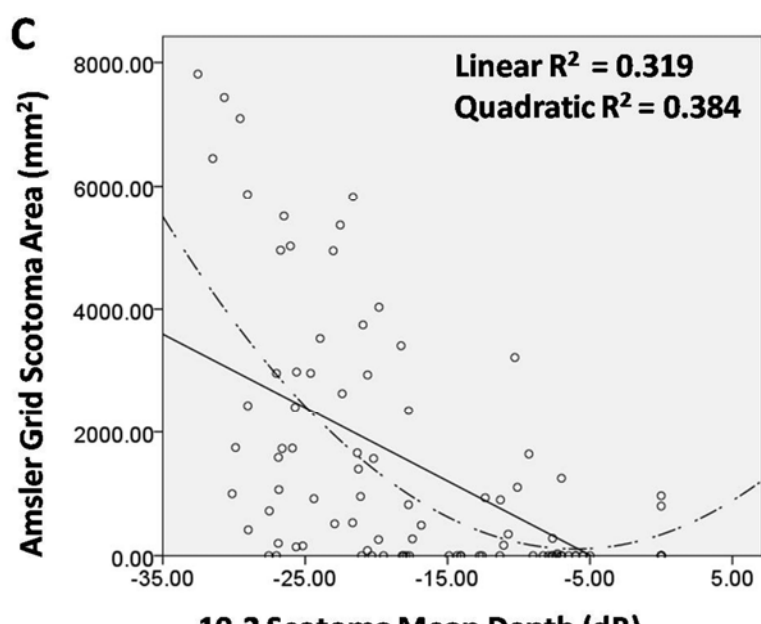
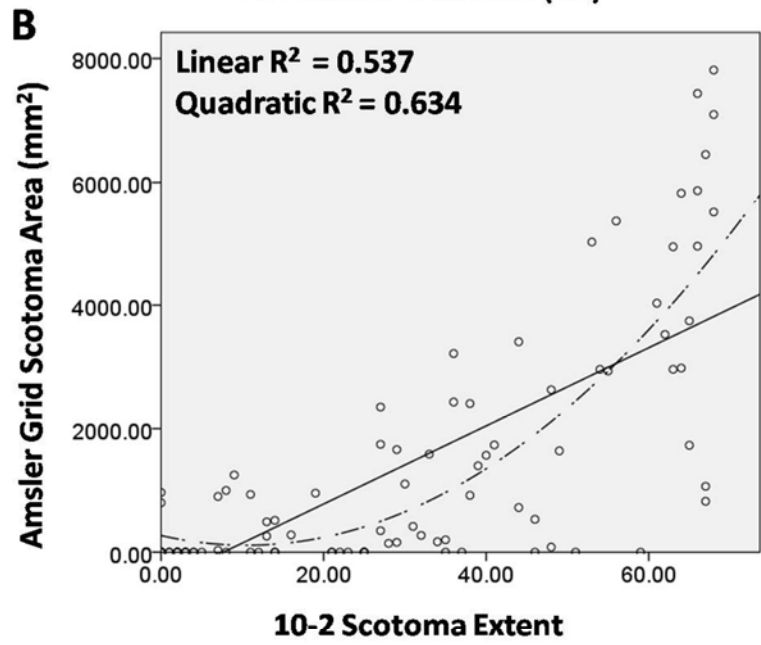
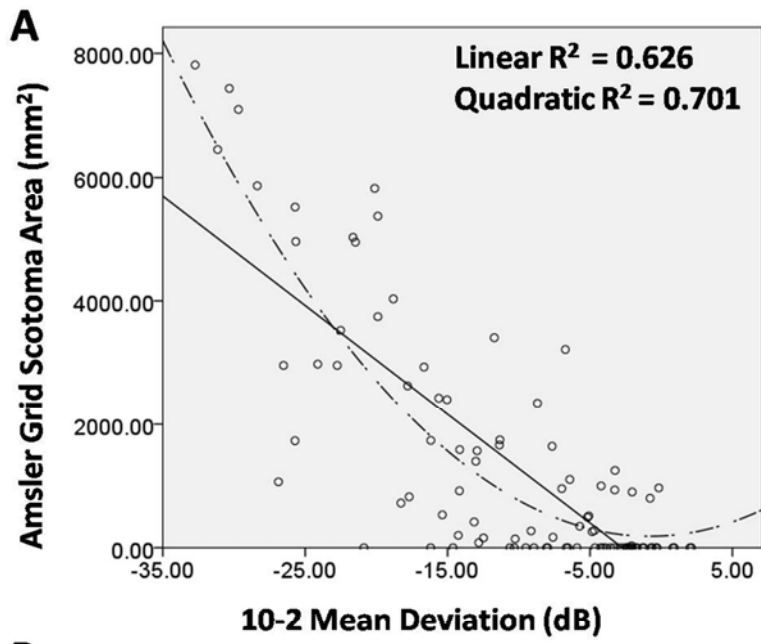
Abstract:

Purpose: To investigate the efficacy of the Amsler grid test compared to 10-2 standard automated perimetry in evaluating central visual field (VF) defects in glaucoma.

Methods: Glaucoma patients with either a normal or abnormal 10-2 VF within the previous 4 months for both eyes were included. Eyes with known macular disease were excluded. An abnormal 10-2 VF was defined as having ≥ 3 adjacent points with $P < 5\%$ and ≥ 1 point with $P < 1\%$. Amsler grid tests were administered for each eye using a black-on-white grid at a distance of 30 cm. The subjects were instructed to outline any perceived scotomas (areas with missing or blurred grid lines) that fall within the central 10 degrees of fixation, which were then defined as 'Amsler grid scotomas'. The area of Amsler grid scotomas were measured using ImageJ software. Correlation analysis and linear and quadratic regression analyses were performed between the Amsler grid scotoma area and 10-2 VF parameters (mean deviation [MD], scotoma extent [number of test points with $P < 1\%$ in total deviation map], and scotoma mean depth [mean value of test points with $P < 1\%$ in total deviation map]).

Results: Ninety-six eyes were enrolled (48 patients, mean age: 67.0 ± 11.8 yr). Mean 24-2 and 10-2 VF MD were -10.44 ± 8.7 dB (range, 0.9 to -30.5) and -10.7 ± 9.0 dB (range, 2.1 to -32.7), respectively. Among 10 eyes with normal 10-2 VF, 8 had normal Amsler grid test. Among 86 eyes with abnormal 10-2 VF, 58 (67%) had abnormal Amsler grid test. The 10-2 MD, 10-2 scotoma extent, and 10-2 scotoma mean depth were significantly correlated with the Amsler grid scotoma area (ρ [rho]= -0.727 , 0.732 , and -0.640 , respectively; all $P < 0.001$). Linear and quadratic regression analyses demonstrated that Amsler grid scotoma area had the strongest relationship with 10-2 MD (linear $R^2=0.626$, quadratic $R^2=0.701$; $P < 0.001$), followed by 10-2 scotoma extent (linear $R^2=0.537$, quadratic $R^2=0.634$; $P < 0.001$), and 10-2 scotoma mean depth (linear $R^2=0.319$, quadratic $R^2=0.384$; $P < 0.001$) (**Fig. A-C**). The Amsler grid appeared to be more useful in detecting moderate to severe 10-2 VF defects.

Conclusions: In glaucoma, the results of the Amsler grid tests approximate the 10-2 VF results. The Amsler grid may be a useful supplement to the 10-2 VF testing for evaluating and monitoring central VF loss in glaucoma.



:

Author Disclosure Information: Andrew Greenberg, None; Daniel Su, None; Joseph Simonson, None; Sung Chul Park, None; Celso Tello, None; Jeffrey Liebmann, Carl Zeiss Meditec, Inc. (C); Robert Ritch, None

Reviewing Code (Complete): 205 glaucoma: visual fields and psychophysics - GL

Presentation Preference (Complete): Paper #1, Poster #2

Keyword (Complete): 754 visual fields ; 626 optic nerve

Clinical Trial/Newsworthy (Complete):

*Does the research presented in your abstract meet the definition of a clinical trial?: No

*Newsworthy: No

Support (Complete):

Do you have grant support?: Yes

*Support : Derald H. Ruttenberg Foundation Research Fund of the New York Glaucoma Research Institute, New York, NY. Dr. Park is the Peter Crowley Research Scientist at the New York Eye and Ear Infirmary

Status: Complete

Genetic Screening of LOXL1 Polymorphisms in Exfoliation Syndrome (XFS) Suspects (XFSS)

Authors: C Pillai¹, W Aalam², T Sullivan¹, J Liebmann¹, R Sharafieh³, M Sarfarazi³, R Ritch¹

Affiliations: ¹ Einhorn Clinical Research Center, New York Eye and Ear Infirmary, New York, New York; ² Ophthalmology Department, Taibah University, Medina, Saudi Arabia; ³ Molecular Ophthalmic Genetics, University of Connecticut Health Center, Farmington, Connecticut.

Clinical trial (www.clinicaltrials.gov): N/A

Funding/support: Joseph M. Cohen Research Fund of the New York Glaucoma Research Institute, New York, NY.

Abstract

Purpose: To assess the potential value of LOXL1 screening in patients with no clinically visible exfoliation material in either eye but with other findings suggestive of XFS.

Methods: We genotyped 17 XFSS for 3 single nucleotide polymorphisms (SNPs; rs3825942, rs1048661 and rs2165241) by direct DNA sequencing. Patients were then risk stratified based on the genotypic prevalence in our database. Those homozygous for all 3 SNPs had only one possible haplotype resulting in a defined risk. Heterozygous patients had >1 possible haplotype and, thus, a range of risk was estimated. A G allele in rs3825942 (G153D) has the strongest association with XFS and, when combined with a G in rs1048661 (R141L) and T in rs2165241, the risk of XFS increases to 700 times that of the normal population (72.78% of XFS subjects vs 43.82% of normal subjects.) This was defined as high risk. Other levels of risk were defined as in the table.

Results: There were 9 women and 8 men (mean age: 59.6±9 years). 5 high risk subjects had GG, GG, TT in R153D, R141L and rs2165241 respectively (GGT haplotype). One patient was classified as medium risk with GA, GG, and CT genotypes. 5 low risk patients had GG, GT, CC genotypes respectively. 2 patients defined as very low risk had genotype AA for G153D. The risk of the remaining 4 patients could not be determined due to their heterozygous genotypes for 2 or more SNPs, resulting in a wide range of possible haplotypes.

Conclusions: This is the first time genetic analysis of LOXL1 polymorphisms has been used for risk stratification of XFSS patients. Although patients homozygous for GGT are at significantly increased risk, determining the prognosis of developing XFS is limited by the low specificity of the genetic markers. Further studies of XFS are warranted to identify markers that may improve the diagnostic yield of genetic screening.

R153D, R141L, rs2165241	XFSS Criteria	Risk
AA, GG, CC	IOP uncontrolled after years of stability	Very Low
GG, GT, CC	Unilateral matte finish to lens	Low
AA, GG, CT	Unilateral Sampaolesi line	Very Low
GG, GG, TT	Tight plateau configuration after LPI	High
GG, GT, CT	Unilateral matte finish to lens	Undetermined
GG, GG, TT	Asymmetric OHT pigment in AC on dilation unilaterally	High
GG, GT, CC	Sampaolesi line in one eye	Low
GG, GT, CT	Asymmetric TM pigmentation	Undetermined
GG, GT, CT	Unilateral matte finish to lens	Undetermined
GG, GG, TT	IOP uncontrolled after years of stability	High
GG, GG, TT	Unilateral glaucoma	High
GG, GT, CC	Unilateral ruff loss and matte finish to lens with IOP elevation after good control of NTG	Low
GG, GT, CC	Unilateral Sampaolesi line	Low
GA, GG, CT	Asymmetric AC pigment dispersion after dilation	Mid
GG, GG, CT	Unilateral Sampaolesi line	High
GG, GT, CT	Unilateral pigment in AC on dilation	Undetermined
GG, GT, CC	Loss of longstanding control of POAG	Low

Variability and Relationships of Lamina Cribrosa Size, Position and Depth in Normal Subjects

Author Block: Reshma A. Mehendale¹, Sung Chul Park^{1,2A}, Joseph Simonson¹, Daniel Su^{1,3}, Amy Mehta², Jeffrey M. Liebmann^{1,4}, Robert Ritch^{1,5}. ¹Einhorn Clinical Research Center, New York Eye & Ear Infirmary, New York, NY; ^AOphthalmology, ²New York Medical College, Valhalla, NY; ³Mount Sinai School of Medicine, New York, NY; ⁴Ophthalmology, NYU School of Medicine, New York, NY; ⁵Ophthalmology, New York Medical College, New York, NY.

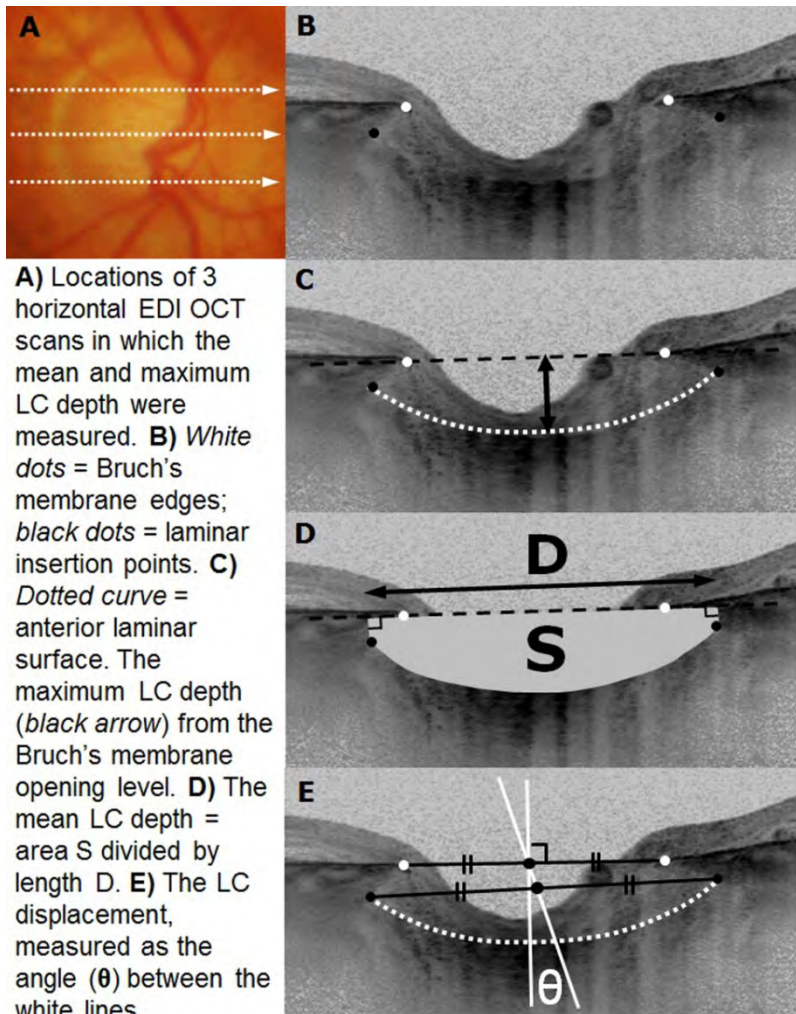
Abstract:

Purpose: To assess size, position and depth of the lamina cribrosa (LC) in normal subjects and their relationships with each other and with axial length, age and intraocular pressure (IOP).

Methods: The mean and maximum LC depths in normal eyes were measured in 3 horizontal enhanced depth imaging optical coherence tomography (EDI OCT) B-scans (midline, mid-superior and mid-inferior; Fig. A-D). The sizes of the optic disc, Bruch's membrane opening (BMO) and LC, defined as the average of their maximum horizontal and vertical diameters, were measured from serial horizontal and vertical EDI OCT B-scans of the optic nerve head (interval between scans: approximately 30 μm). Using the horizontal midline EDI OCT B-scan, the LC displacement from the BMO was measured as an angle (θ) (Fig. E). Univariate and multivariate correlation analyses were performed between these measured variables (the sizes of the optic disc, BMO and LC, the mean and maximum LC depths, and $|\theta|$), axial length, age and IOP.

Results: 45 eyes (45 subjects) were included (mean age and axial length: 41 ± 17 yr and 24.4 ± 1.4 mm [range: 21.9 to 27.8], respectively). The LC size (1893 ± 205 μm [range: 1437 to 2397]), the LC displacement (θ) (29 ± 29 degrees [range: -45 to 78]) and the mean (348 ± 76 μm [range: 240 to 499]) and maximum (399 ± 81 μm [range: 276 to 561]) LC depths varied considerably among eyes. The LC size significantly correlated with the optic disc size ($P=0.002$, $R=0.587$) and the BMO size ($P=0.001$, $R=0.603$), but not with axial length, age or IOP (all $P>0.3$). The absolute LC displacement ($|\theta|$) significantly correlated with axial length ($P<0.001$, ρ [rho] = 0.697), but not with age, IOP or the sizes of the optic disc, BMO and LC (all $P>0.1$). Both mean and maximum LC depths significantly correlated with the LC size ($P=0.006$, $R=-0.533$ for mean LC depth; $P=0.007$, $R=-0.526$ for maximum LC depth) and the absolute LC displacement ($|\theta|$) ($P=0.018$, $R=-0.471$ for mean LC depth; $P=0.029$, $R=-0.439$ for maximum LC depth), but not with axial length, age or IOP (all $P>0.2$). In the multivariate analysis, the correlation of LC depth with the LC size and the absolute LC displacement ($|\theta|$) remained significant ($P \leq 0.036$).

Conclusions: The LC size, position and depth vary considerably among eyes. The LC depth has a moderate correlation with the LC size and displacement.



Author Disclosure Information: Reshma A. Mehendale, None; Sung Chul Park, None; Joseph Simonson, None; Daniel Su, None; Amy Mehta, None; Jeffrey M. Liebmann, Heidelberg Engineering, GmbH (F), Optovue, Inc. (C), Topcon, Inc. (C); Robert Ritch, None

Reviewing Code (Complete): 220 imaging: OCT advances in technology - MOI

Presentation Preference (Complete): Paper #1, Poster #2

Keyword (Complete): 626 optic nerve ; 551 imaging methods (CT, FA, ICG, MRI, OCT, RTA, SLO, ultrasound) ; 419 anatomy

Clinical Trial/Newsworthy (Complete):

*Does the research presented in your abstract meet the definition of a clinical trial?: No

*Newsworthy: No

Support (Complete):

Do you have grant support?: Yes

*Support : Supported by HRH Prince Abdulaziz bin Ahmed bin Abdulaziz Al-Saud Research Fund of the New York Glaucoma Research Institute, NY, NY. Dr. Park is the Peter Crowley Research Scientist at the NYEEI.

Status: Complete

Treatment of Acute Subretinal Hemorrhage with Subretinal Tissue Plasminogen Activator Administered via Pars Plana Vitrectomy and Gas Fluid Exchange

David Warrow, MD Julia P. Shulman, MD Jonathan A. Feistmann, MD Michael P. Teske, MD, Richard B. Rosen, MD

Objective: To evaluate the efficacy of subretinal tissue plasminogen activator (tPA) injection administered via pars plana vitrectomy (PPV) and gas fluid exchange (GFE) to treat acute submacular hemorrhage.

Purpose: To assess therapeutic outcomes, specifically the change in best-corrected visual acuity (BCVA) and post-operative complication rate, of performing PPV and GFE with subretinal tPA administration to treat acute submacular hemorrhage. Additional analysis of etiology and the presence of sub-retinal pigment epithelial (RPE) hemorrhage and their respective effects on visual outcome will be performed.

Methods: The charts of 37 patients with acute submacular hemorrhage were reviewed in this retrospective, noncomparative, interventional case series. PPV with GFE and subretinal tPA administration for each patient was performed between October 2003 and September 2011 at either the New York Eye and Ear Infirmary or Moran Eye Center. Clinical data captured included patient age, diagnosis, presence of sub-RPE hemorrhage, ophthalmic comorbidities, use of blood thinners, pre- and peri-operative management, pre- and post-operative month six logMAR BCVA and complications. Clinical endpoints considered were change in BCVA, rate of visual improvement, and complication rate.

Results: Mean age was 72 ± 15 years (range 26-91). 24 of 37 patients (65%) had neovascular age-related macular degeneration (AMD), 6 (16%) had polypoidal choroidal vasculopathy, 4 (11%) had a macroaneurysm, 2 (5%) had traumatic choroidal rupture, and 1 (3%) had choroidal neovascularization secondary to toxoplasmosis. 26 (70%) cases had sub-RPE hemorrhage. 18 (49%) patients took blood thinners. Mean pre-op BCVA was 1.74, mean post-op month 6 BCVA was 1.42. Postoperative retinal detachment, recurrent submacular hemorrhage, persistent vitreous hemorrhage, or macular hole occurred in 7 (19%) cases. For AMD patients, mean BCVA improved from 1.72 to 1.46, and for non-AMD patients, it improved from 1.78 to 1.34 ($p = 0.52$). In cases with sub-RPE blood, mean BCVA improved from 1.82 to 1.69, and in cases without sub-RPE blood, BCVA improved from 1.56 to 0.87 ($p = 0.04$). 7 of 26 (27%) of patients with sub-RPE blood gained vision, while 8 of 11 (73%) patients without sub-RPE blood gained vision ($p = 0.03$).

Conclusion: The use of subretinal tPA via PPV with GFE for acute submacular hemorrhage improved vision at six months post-op. Patients with neovascular AMD demonstrated less improvement in BCVA than patients with other etiologies. Sub-RPE blood led to reduced improvement in mean BCVA and a lower rate of visual gain from pre-op level than in cases without sub-RPE blood, in a statistically significant manner.